National Comprehensive Cancer Network®

NCCN Clinical Practice Guidelines in Oncology (NCCN Guidelines®)

Histiocytic Neoplasms

Version 2.2025 — November 21, 2025

NCCN recognizes the importance of clinical trials and encourages participation when applicable and available. Trials should be designed to maximize inclusiveness and broad representative enrollment.

Version 2.2025, 11/21/25 © 2025 National Comprehensive Cancer Network® (NCCN®), All rights reserved. NCCN Guidelines® and this illustration may not be reproduced in any form without the express written permission of NCCN.

PLEASE NOTE that use of this NCCN Content is governed by the End-User License Agreement, and you MAY NOT distribute this Content or use it with any artificial intelligence model or tool.
Printed by Máximo López Chenlo on 5/4/2026 6:21:12 PM. Copyright © 2026 National Comprehensive Cancer Network, Inc. All Rights Reserved.

***Ronald S. Go, MD / Chair ‡**
Mayo Clinic Comprehensive Cancer Center

***Eric Jacobsen, MD / Vice-Chair †**
Dana-Farber/Brigham and Women's Cancer Center | Mass General Cancer Center

Rita Assi, MD ‡
Indiana University Melvin and Bren Simon Comprehensive Cancer Center

Robert Baiocchi, MD, PhD †
The Ohio State University Comprehensive Cancer Center - James Cancer Hospital and Solove Research Institute

***Ilia Buhtoiarov, MD €**
Case Comprehensive Cancer Center/University Hospitals Seidman Cancer Center and Cleveland Clinic Taussig Cancer Institute

Erin B. Butler, MD €
UT Southwestern Simmons Comprehensive Cancer Center

Patrick K. Campbell, MD, PhD €
St. Jude Children's Research Hospital/ The University of Tennessee Health Science Center

Eli Diamond, MD Ψ
Memorial Sloan Kettering Cancer Center

Michael Drazer, MD, PhD ‡
The UChicago Medicine Comprehensive Cancer Center

Denis M. Dwyre, MD ≠
UC Davis Comprehensive Cancer Center

Aron Flagg, MD € ξ ‡
Yale Cancer Center/Smilow Cancer Hospital

Deanna Fournier, BA ¥
Histiocytosis Association

Aaron M. Goodman, MD ξ
UC San Diego Moores Cancer Center

Gaurav Goyal, MD ‡ †
O'Neal Comprehensive Cancer Center at UAB

Dita Gratzinger, MD, PhD ≠
Stanford Cancer Institute

Paul C. Hendrie, MD, PhD ‡
Fred Hutchinson Cancer Center

Meghan Higman, MD, PhD ‡ € ξ
Roswell Park Comprehensive Cancer Center

Michael D. Hogarty, MD €
Abramson Cancer Center at the University of Pennsylvania

Ah-Reum Jeong, MD Þ ‡
UC San Diego Moores Cancer Center

Reem Karmali, MD, MS ‡
Robert H. Lurie Comprehensive Cancer Center of Northwestern University

Nicole Karras, MD €
City of Hope National Medical Center

Jerry Lee, MD, MPhil, MS Þ † ‡ ξ
UCSF Helen Diller Family Comprehensive Cancer Center

Naveen Manchanda, MD ‡
Indiana University Melvin and Bren Simon Comprehensive Cancer Center

David Morgan, MD ‡ ξ
Vanderbilt-Ingram Cancer Center

Douglas E. Ney, MD Ψ
University of Colorado Cancer Center

Ann C. Raldow, MD, MPH §
UCLA Jonsson Comprehensive Cancer Center

Chittalsinh Raulji, MBBS €
Fred & Pamela Buffett Cancer Center

Alexandra Stefanovic, MD ‡ †
Duke Cancer Institute

Devaki Shilpa Surasi, MD ϕ
The University of Texas MD Anderson Cancer Center

Srinivas K. Tantravahi, MBBS, MRCP ‡
Huntsman Cancer Institute at the University of Utah

Kelly Walkovich, MD €
University of Michigan Rogel Cancer Center

Jian (Michael) Yu, MD ϕ
Fox Chase Cancer Center

Elias Zambidis, MD, PhD ‡
Johns Hopkins Kimmel Cancer Center

Ling Zhang, MD ≠ ‡
Moffitt Cancer Center

Luke Zurbriggen, MD ‡ Þ
University of Wisconsin Carbone Cancer Center

NCCN
Ajibola Awotiwon, MBBS, MSc
Nicholas Sansone, MFA
Bailee Sliker, PhD

ξ Bone marrow transplantation
‡ Hematology/Hematology oncology
Þ Internist/Internal medicine, including family practice, preventive management
† Medical oncology
Ψ Neurology/Neuro-oncology
ϕ Nuclear medicine
≠ Pathology
¥ Patient advocacy
€ Pediatric oncology
§ Radiotherapy/radiation oncology
* Discussion Writing Committee Member

NCCN Guidelines Panel Disclosures

PLEASE NOTE that use of this NCCN Content is governed by the End-User License Agreement, and you MAY NOT distribute this Content or use it with any artificial intelligence model or tool.
Printed by Máximo López Chenlo on 5/4/2026 6:21:12 PM. Copyright © 2026 National Comprehensive Cancer Network, Inc. All Rights Reserved.

NCCN Guidelines Version 2.2025
Histiocytic Neoplasms

NCCN Histiocytic Neoplasms Panel Members
Summary of the Guidelines Updates

Adult Langerhans Cell Histiocytosis:
- Workup/Evaluation (ADULCH-1)
- Tissue Biopsy Analysis for LCH (ADULCH-1A)
- Uncomplicated Unifocal LCH (ADULCH-2)
- Multisystem or Multifocal Single-System LCH or Unifocal LCH that Progresses on Local Therapy or Involves Critical Organs (ADULCH-3)
- Follow-Up, Treatment for Relapsed/Refractory Disease (ADULCH-4)

Pediatric Langerhans Cell Histiocytosis:
- Workup/Evaluation (PEDLCH-1)
- Tissue Biopsy Analysis for LCH (PEDLCH-1A)
- Unifocal LCH (PEDLCH-2)
- Multisystem LCH or Unifocal LCH that Progresses on Local Therapy or Unifocal LCH Involving Critical Organs (PEDLCH-3)
- Follow-Up, Treatment for Relapsed/Refractory Disease (PEDLCH-4)

Erdheim-Chester Disease:
- Workup/Evaluation (ECD-1)
- Tissue Biopsy Analysis for ECD (ECD-1A)
- Presentation (ECD-2)

Rosai-Dorfman Disease:
- Workup/Evaluation (RDD-1)
- Tissue Biopsy Analysis for RDD (RDD-1A)
- Unifocal/Multifocal RDD (RDD-2)

Principles of Diagnostic Evaluation (HIST-A)
Characteristic Features of Histiocytic Neoplasms (HIST-B)
Principles of Pathology (HIST-C)
Principles of Systemic Therapy (HIST-D)
Principles of Supportive Care (HIST-E)
Principles of Targeted Therapy (HIST-F)
Principles of Radiation Therapy (HIST-G)

Abbreviations (ABBR-1)

Find an NCCN Member Institution: https://www.nccn.org/home/member-institutions.

NCCN Categories of Evidence and Consensus: All recommendations are category 2A unless otherwise indicated.

See NCCN Categories of Evidence and Consensus.

NCCN Categories of Preference: All recommendations are considered appropriate.

See NCCN Categories of Preference.

The NCCN Guidelines® are a statement of evidence and consensus of the authors regarding their views of currently accepted approaches to treatment. Any clinician seeking to apply or consult the NCCN Guidelines is expected to use independent medical judgment in the context of individual clinical circumstances to determine any patient's care or treatment. The National Comprehensive Cancer Network® (NCCN®) makes no representations or warranties of any kind regarding their content, use or application and disclaims any responsibility for their application or use in any way. The NCCN Guidelines are copyrighted by National Comprehensive Cancer Network®. All rights reserved. The NCCN Guidelines and the illustrations herein may not be reproduced in any form without the express written permission of NCCN. ©2025.

PLEASE NOTE that use of this NCCN Content is governed by the End-User License Agreement, and you MAY NOT distribute this Content or use it with any artificial intelligence model or tool.
Printed by Máximo López Chenlo on 5/4/2026 6:21:12 PM. Copyright © 2026 National Comprehensive Cancer Network, Inc. All Rights Reserved.

Updates in Version 2.2025 of the NCCN Guidelines for Histiocytic Neoplasms include:

New Algorithm and Principles of Systemic Therapy
• Pediatric Langerhans Cell Histiocytosis (PEDLCH-1 and HIST-D 3)
Principles of Diagnostic Evaluation
HIST-A 2
• Laboratory Evaluation, 6th bullet added: For pediatric LCH: Coagulation panel, plasma and urine osmolality, urinalysis/urine specific gravity
• Subspecialty Consultations as Needed, 4th bullet revised: Endocrinology*, especially for pediatric LCH to evaluate pituitary gland involvement*
Principles of Pathology
HIST-C 1
• Langerhans Cell Histiocytosis, 6th bullet added: Approximately 50% of pediatric LCH cases demonstrate a BRAF V600E mutation. In those with non-BRAF V600E-mutated LCH, NGS revealed the prevalence of other somatic mutations: MAP2K1 exon 2 or 3 mutations (42%), BRAF exon 12 deletions and duplications (32%), other BRAF V600 codon mutation (4%), and non-MAPK pathway genes (4%).
Principles of Radiation Therapy
HIST-G
• Heading added: Pediatric and Adult Langerhans Cell Histiocytosis
• Heading revised: General Guidelines~~ - Langerhans Cell Histiocytosis~~
• RT Dosing, 1st bullet revised: There exists a wide range of experience with treatment doses ~~for LCH~~...

Updates in Version 1.2025 of the NCCN Guidelines for Histiocytic Neoplasms include:
Global
• References updated throughout the guideline.
New Principles
• Principles of Targeted Therapy (HIST-F)
• Principles of Radiation Therapy (HIST-G)
Langerhans Cell Histiocytosis
LCH-1
• Essential
  ▸ 4th bullet, 1st sub-bullet added: If unexplained complete blood count (CBC) abnormality, consider bone marrow biopsy to assess for hemophagocytic lymphohistiocytosis, LCH, and/or associated myeloid neoplasm
• Useful Under Certain Circumstances:
  ▸ 2nd bullet, 3rd sub-bullet revised: sella turcica ± pituitary (if ~~diabetes insipidus~~ *arginine vasopressin [AVP] deficiency* suspected) (Also for ECD-1, RDD-1)
  ▸ 7th bullet revised: Endocrine evaluation (essential in detected endocrinopathy or *in cases of* pituitary/hypothalamic involvement)
• Algorithm pathway revised:
  ▸ Tissue biopsy analysis and CBC abnormality (LCH-2) removed.
  ▸ Uncomplicated unifocal LCH → LCH-2 added.
  ▸ Multisystem or multifocal single-system LCH or Unifocal LCH that progresses on local therapy or Unifocal LCH involving critical organs (ie, central nervous system [CNS], liver, spleen) → LCH-3 added.
• Footnote c revised: Common sites of involvement include: bone, *bone marrow*, skin, *gastrointestinal (GI) system*, lymph node, liver, spleen, oral mucosa, lung, and central nervous system (CNS). See Characteristic Features of Histiocytic Neoplasms (HIST-B).
• Footnote removed: It is recommended for imaging studies to be performed with contrast, unless contrast is contraindicated (Also for ECD-1, RDD-1)
• Footnote f added: Previously known as diabetes insipidus. (Also for ECD-1, RDD-1, HIST-B 1)

Continued

Version 2.2025, 11/21/25 © 2025 National Comprehensive Cancer Network® (NCCN®), All rights reserved. NCCN Guidelines® and this illustration may not be reproduced in any form without the express written permission of NCCN.

PLEASE NOTE that use of this NCCN Content is governed by the End-User License Agreement, and you MAY NOT distribute this Content or use it with any artificial intelligence model or tool.
Printed by Máximo López Chenlo on 5/4/2026 6:21:12 PM. Copyright © 2026 National Comprehensive Cancer Network, Inc. All Rights Reserved.

Updates in Version 1.2025 of the NCCN Guidelines for Histiocytic Neoplasms include:

LCH-1A
- Molecular testing
  - 1st sub-bullet revised: Target capture, next-generation sequencing (NGS) study including *BRAF V600E*, MAPK, and related pathway mutations on tissue (Also for ECD-1A)
  - Bullet removed: BRAF V600E (VE1) immunohistochemistry (Also for ECD-1A, RDD-1A)
- Algorithm pathway CBC abnormality removed. (Also for ECD-1A)
- Footnote h revised: ~~A minimal~~ *At minimum, the IHC* panel recommended *should includes* ~~would include~~ CD1a, S100, and Langerin; cyclin D1, and BRAF V600E (VE1, *preferred antibody if possible*) ~~immunohistochemistry is recommended~~.
- Footnote i revised: ~~Somatic mutation~~ *Targeted* NGS panel testing should cover the common *somatic mutations involving the* MAPK pathway ~~mutations~~. RNA-based molecular panel including fusion testing should cover BRAF, ALK, RET, and NTRK1 rearrangements. ~~If there is clinical concern for ALK rearrangement, or if fusion panel testing is not available, ALK IHC and fluorescence in situ hybridization (FISH) studies may be performed.~~ *If there is clinical concern for ALK-positive histiocytosis, ALK IHC and fluorescence in situ hybridization (FISH) using ALK break-apart probe should be performed.* (Also for ECD-1A)

Langerhans Cell Histiocytosis (continued)

LCH-2
- Presentation: *Uncomplicated* unifocal LCH
- Treatment, Isolated bone involvement, 5th bullet modified: Radiation therapy (RT) ~~(low-dose)~~
- Treatment, Isolated skin disease, 5th bullet modified: RT ~~(low-dose)~~
- Footnote added: See Principles of Radiation Therapy (HIST-G). (Also for LCH-3)

LCH-4
- Heading added: Treatment response assessment
- Imaging of involved sites, 1st bullet modified: FDG-PET/CT scan vertex to toes (preferred) *or contrast-enhanced* CT/MRI
- Heading revised: Surveillance *of patients on observation or in remission*
- Follow-up, Surveillance
  - 1st bullet modified: H&P and labs *at least annually or more frequently* as clinically indicated (Also for RDD-3)
  - 2nd bullet modified: Imaging: FDG-PET/CT scan vertex to toes (preferred) *or contrast-enhanced* CT/MRI
  - 2nd bullet, 1st sub-bullet modified: ~~Every 3–6 months for the first 2 years~~ *No more than every 6 months for up to 2 years* post completion of treatment
  - 3rd bullet modified: Monitor PFTs every ~~3–6~~ *6–12* months for ~~at least~~*up to* 2 years for pulmonary LCH *with follow-up as clinically indicated*
  - 4th bullet modified: Bone marrow evaluation in the presence of unexplained *CBC abnormality*~~cytopenias or other blood count abnormalities~~ (to rule out *HLH, LCH, and/or* associated myeloid neoplasm)
- After Treatment for Relapsed/Refractory Disease, added: (See NCCN Guidelines for Survivorship)

Continued

Version 2.2025, 11/21/25 © 2025 National Comprehensive Cancer Network® (NCCN®), All rights reserved. NCCN Guidelines® and this illustration may not be reproduced in any form without the express written permission of NCCN.

PLEASE NOTE that use of this NCCN Content is governed by the End-User License Agreement, and you MAY NOT distribute this Content or use it with any artificial intelligence model or tool.
Printed by Máximo López Chenlo on 5/4/2026 6:21:12 PM. Copyright © 2026 National Comprehensive Cancer Network, Inc. All Rights Reserved.

Updates in Version 1.2025 of the NCCN Guidelines for Histiocytic Neoplasms include:

Erdheim-Chester Disease

ECD-1

- Essential
  - 3rd bullet, 1st sub-bullet added: If unexplained CBC abnormality, consider bone marrow biopsy to assess for hemophagocytic lymphohistiocytosis, ECD, and/or associated myeloid neoplasm

ECD-1A

- Footnote i modified: ~~A minimal~~ *At minimum, the IHC* panel recommended *should include*~~s would include~~ CD68 or CD163, factor XIIIa, S100, and CD1a, and *BRAF* V600E (VE1, preferred antibody if possible) ~~immunohistochemistry is recommended~~.

ECD-2

- Follow-up
  - 1st bullet modified: FDG-PET/CT scan *no more than* every 6 months after starting therapy until stabilization of the disease, and as clinically indicated after 2 years
  - 2nd bullet modified: Organ-specific imaging (CT with contrast or MRI with and without contrast) *no more than* every 6 months until disease stabilization and then every 6–12 months
  - 5th bullet added: Perform bone marrow biopsy as indicated
  - 6th bullet modified: Monitor every 1–2 years for *hypothalamic* pituitary ~~hormone~~ *axis* abnormalities *with hormone testing as indicated*

Rosai-Dorfman Disease

RDD-1A

- IHC, 1st bullet modified: S100+, CD68+, CD163+, cyclin D1+/-, CD1a-, Langerin-, OCT2+*, BRAF V600E (VE1)*
- Molecular testing: 1st bullet modified: Target capture, NGS study including *BRAF V600E*, MAPK, and related pathway mutations on tissue
- Footnote g modified: ~~A minimal panel would include CD68 or CD163, S100, CD1a, and cyclin D1.~~ *At minimum, the IHC panel recommended should include CD68 or CD163, S100, CD1a; cyclin D1* and *BRAF* V600E (VE1, *preferred antibody if possible*). *Of caution, cyclin D1 could also be positive or detected in concurrent lymphocytic or histiocytic neoplasm. VE1 is the preferred antibody for BRAF V600E testing if possible.*
- Footnote i modified: If a familial RDD is suspected, germline mutations in SLC29A3 should be considered. A*nother* germline gene mutation involving the Fas gene ~~is~~ TNFRSF6~~ was~~, *which is* found in 40% of patients with RDD who had an *autoimmune lymphoproliferative syndrome* (ALPS) type Ia.

RDD-2

- Follow-up
  - Treatment response assessment modified: Imaging of involved sites (FDG-PET/CT scan [preferred] *or contrast-enhanced* CT/MRI)
  - Surveillance of patients on observation or in remission:
    - ◊ 1st bullet modified: H&P and labs *at least annually or more frequently* as clinically indicated
    - ◊ 2nd bullet modified: FDG-PET/CT scan *no more than* every 6 months after starting therapy until stabilization of the disease
    - ◊ 3rd bullet modified: Organ-specific imaging (CT with contrast or MRI with and without contrast) *no more than* every 6 months until disease stabilization and then every 6–12 months

Continued

Version 2.2025, 11/21/25 © 2025 National Comprehensive Cancer Network® (NCCN®), All rights reserved. NCCN Guidelines® and this illustration may not be reproduced in any form without the express written permission of NCCN.

PLEASE NOTE that use of this NCCN Content is governed by the End-User License Agreement, and you MAY NOT distribute this Content or use it with any artificial intelligence model or tool.
Printed by Máximo López Chenlo on 5/4/2026 6:21:12 PM. Copyright © 2026 National Comprehensive Cancer Network, Inc. All Rights Reserved.

Updates in Version 1.2025 of the NCCN Guidelines for Histiocytic Neoplasms include:

Principles of Diagnostic Evaluation

HIST-A 1

- Medical History and Physical Examination
  - 3rd bullet modified: Cardiovascular: dyspnea, orthopnea, hypertension, irregular pulse, bradycardia, *tachycardia,* cardiomegaly, murmurs
  - 7th bullet modified: Abdominal/gastrointestinal (GI): diarrhea, melena, flank mass, hepatosplenomegaly~~, enlarged inguinal nodes~~, abdominal pain, constipation, hematochezia
  - 8th bullet modified: Genital: testicular *or epididymal* mass or enlargement

HIST-A 2

- Subspecialty Consultations as Needed, bullet added: Cardiology.

Characteristic Features of Histiocytic Neoplasms

HIST-B 1

- Table modified:
  - Endocrine
    - ECD: Central ~~diabetes insipidus (DI)~~ *AVP deficiency* may present years before diagnosis of ECD
    - LCH: ~~DI~~ *AVP deficiency* may present years before diagnosis of LCH
    - RDD: ~~DI~~ *AVP deficiency* never reported
  - Dermatologic, RDD: ~~More common s~~*S*ubcutaneous nodules, may be seen as macular or papular rash *that varies in color*

Principles of Pathology

HIST-C 2

- Rosai-Dorfman Disease
  - 4th bullet, 1st sub-bullet modified: *Another h*~~H~~eterozygous germline gene mutation involving *the* FAS gene *is* TNFRSF6, which is found in 40% of patients with RDD who had an ALPS type Ia.

Principles of Systemic Therapy

HIST-D 1

- Footnote b was modified: ~~Consider~~*Recommend* starting targeted agents at lower dose. (Also for HIST-D 2, HIST-D 3, HIST-D 4)
- Footnote c was modified: ~~See Management of Toxicities Associated with Targeted and Immune Therapies (ME-K) in the NCCN Guidelines for Melanoma: Cutaneous.~~*See Principles of Targeted Therapy (HIST-F)*.
- Footnote d was added: Some therapies have not been studied in histiocytic disease; thus, some data are being extrapolated from other disease sites. (Also for HIST-D 2, HIST-D 3, HIST-D 4)

HIST-D 5

- Reference 25 added: Solomon B, Drilon A, Lin JJ, et al. Repotrectinib in patients with NTRK fusion-positive advanced solid tumors, including non-small cell lung cancer: update from the phase 1/2 TRIDENT-1 trial. Poster presented at the European Society for Medical Oncology Congress, Madrid, Spain, October 20-24, 2023.

Principles of Supportive Care

HIST-E

- Toxicities of BRAF and MEK Inhibitors section removed.
- Toxicities of Other Targeted Therapies section removed.
- Chronic Pain, Fatigue, Depression, Anxiety, and Poor Quality of Life
  - 11th bullet, added link: Survivorship.

Version 2.2025, 11/21/25 © 2025 National Comprehensive Cancer Network® (NCCN®), All rights reserved. NCCN Guidelines® and this illustration may not be reproduced in any form without the express written permission of NCCN.

PLEASE NOTE that use of this NCCN Content is governed by the End-User License Agreement, and you MAY NOT distribute this Content or use it with any artificial intelligence model or tool.
Printed by Máximo López Chenlo on 5/4/2026 6:21:12 PM. Copyright © 2026 National Comprehensive Cancer Network, Inc. All Rights Reserved.

INTRODUCTION

These Guidelines describe treatment recommendations for adults and children with histiocytic neoplasms. In scenarios where there is little evidence in the adult population, recommendations are extrapolated from pediatric studies.

Version 2.2025, 11/21/25 © 2025 National Comprehensive Cancer Network® (NCCN®), All rights reserved. NCCN Guidelines® and this illustration may not be reproduced in any form without the express written permission of NCCN.

PLEASE NOTE that use of this NCCN Content is governed by the End-User License Agreement, and you MAY NOT distribute this Content or use it with any artificial intelligence model or tool.
Printed by Máximo López Chenlo on 5/4/2026 6:21:12 PM. Copyright © 2026 National Comprehensive Cancer Network, Inc. All Rights Reserved.

WORKUP / EVALUATION[a]

ESSENTIAL:

- History and physical examination (H&P)[b] with attention to common sites of involvement[c]
- Whole-body fluorodeoxyglucose (FDG)-PET/CT scan including distal extremities (vertex to toes)
- Pulmonary function tests (PFTs) and high-resolution CT (HRCT) of the chest for suspected pulmonary Langerhans cell histiocytosis (LCH)
- Laboratory evaluation[b]
  - If unexplained complete blood count (CBC) abnormality, consider bone marrow biopsy to assess for hemophagocytic lymphohistiocytosis, LCH, and/or associated myeloid neoplasm[d]
- Tissue biopsy[e] (ADULCH-1A)

USEFUL UNDER CERTAIN CIRCUMSTANCES, BASED ON SYMPTOMS OR ORGAN INVOLVEMENT:

- CT of the chest, abdomen, and pelvis with contrast
- MRI with and without contrast for the following:
  - brain
  - spine
  - sella turcica ± pituitary (if arginine vasopressin [AVP] deficiency[f] suspected)
- Right heart catheterization if pulmonary hypertension is suspected
- Transthoracic echocardiogram (TTE) especially for pulmonary LCH
- Ultrasound (US) of the abdomen (liver/spleen)
- Endoscopic retrograde cholangiopancreatography (ERCP) (if LFTs abnormal or ducts dilated on CT/US)
- Endocrine evaluation (essential in detected endocrinopathy or in cases of pituitary/hypothalamic involvement)
- Digital panoramic x-ray

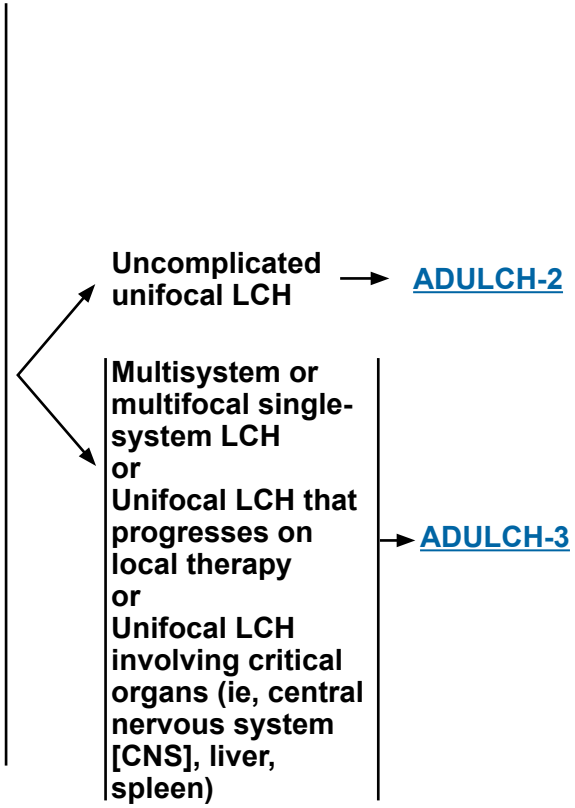

[a] Adapted with permission from Goyal G, et al. Blood 2022;139:2601-2621.
[b] Principles of Diagnostic Evaluation (HIST-A).
[c] Common sites of involvement include: bone, bone marrow, skin, gastrointestinal (GI) system, lymph node, liver, spleen, oral mucosa, lung, and CNS. See Characteristic Features of Histiocytic Neoplasms (HIST-B).
[d] See NCCN Guidelines for Myelodysplastic Syndromes or NCCN Guidelines for Myeloproliferative Neoplasms.
[e] Principles of Pathology (HIST-C).
[f] Previously known as diabetes insipidus.

Note: All recommendations are category 2A unless otherwise indicated.

Version 2.2025, 11/21/25 © 2025 National Comprehensive Cancer Network® (NCCN®), All rights reserved. NCCN Guidelines® and this illustration may not be reproduced in any form without the express written permission of NCCN.

PLEASE NOTE that use of this NCCN Content is governed by the End-User License Agreement, and you MAY NOT distribute this Content or use it with any artificial intelligence model or tool.
Printed by Máximo López Chenlo on 5/4/2026 6:21:12 PM. Copyright © 2026 National Comprehensive Cancer Network, Inc. All Rights Reserved.

TISSUE BIOPSY ANALYSIS FOR LCH

Tissue biopsy[g] →

- **Morphology**
  - **Histiocytes with grooved nuclei, eosinophilia**

→

- **Immunohistochemistry (IHC)[h]**
  - **CD1a+, Langerin (CD207)+, S100+, cyclin D1+, *BRAF* V600E (VE1)+/-**

→

- **Molecular testing[g,i]**
  - **Target capture, next-generation sequencing (NGS) study including *BRAF* V600E, MAPK, and related pathway mutations on tissue[j]**
  - **Gene fusion assay**

Immunophenotype key: +/-: positive or negative; +: positive; -: negative

[g] For patients with suspected LCH or histiocytosis and biopsy is not possible because of location or risk factors, mutational analysis of the peripheral blood is an option.
[h] At minimum, the IHC panel recommended should include CD1a, S100, and Langerin; cyclin D1 and *BRAF* V600E (VE1, preferred antibody if possible).
[i] Molecular testing for somatic mutations and fusions can be performed in a stepwise manner or in parallel, depending on clinical need and institutional protocols. The frequency of suspected molecular lesions should drive the order of testing if a stepwise algorithm is chosen. Allele-specific polymerase chain reaction (PCR) for *BRAF* V600E mutations can be the first step if *BRAF* V600E (VE1) IHC is not available or is equivocal. Targeted NGS panel testing should cover the common somatic mutations involving the MAPK pathway. RNA-based molecular panel including fusion testing should cover *BRAF*, *ALK*, *RET,* and *NTRK1* rearrangements. If there is clinical concern for *ALK*-positive histiocytosis, ALK IHC and fluorescence in situ hybridization (FISH) using ALK break-apart probe should be performed.
[j] Fresh or paraffin-embedded tissue is used for NGS study; peripheral blood may be informative in multisystem disease. The NGS panel should cover the common MAPK pathway mutations (ie, *BRAF, ARAF, NRAS, KRAS, MAP2K1/2)* and other related pathway mutations (eg, *PIK3CA*, *CSF1R)*.

Note: All recommendations are category 2A unless otherwise indicated.

Version 2.2025, 11/21/25 © 2025 National Comprehensive Cancer Network® (NCCN®), All rights reserved. NCCN Guidelines® and this illustration may not be reproduced in any form without the express written permission of NCCN.

PLEASE NOTE that use of this NCCN Content is governed by the End-User License Agreement, and you MAY NOT distribute this Content or use it with any artificial intelligence model or tool.
Printed by Máximo López Chenlo on 5/4/2026 6:21:12 PM. Copyright © 2026 National Comprehensive Cancer Network, Inc. All Rights Reserved.

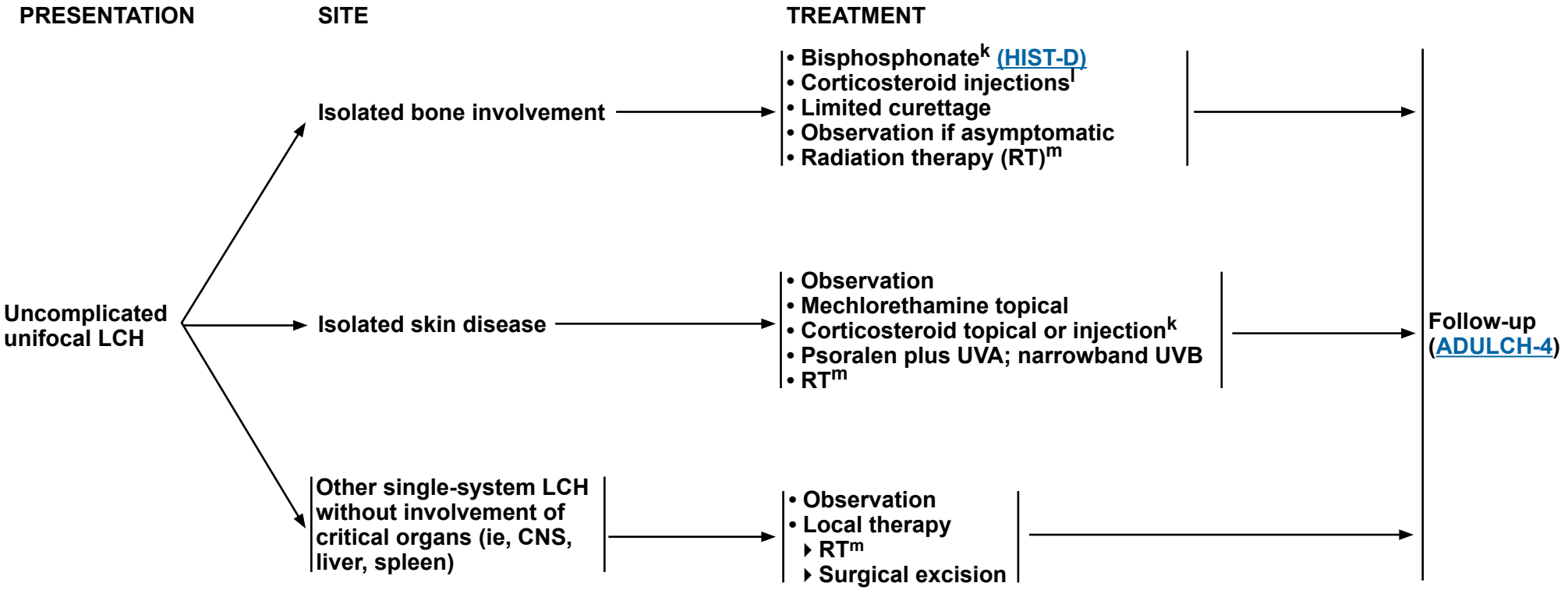

[k] Bone lesions not amenable to local therapies due to size and location.
[l] Triamcinolone injection or equivalent corticosteroid.
[m] Principles of Radiation Therapy (HIST-G).

Note: All recommendations are category 2A unless otherwise indicated.

Version 2.2025, 11/21/25 © 2025 National Comprehensive Cancer Network® (NCCN®), All rights reserved. NCCN Guidelines® and this illustration may not be reproduced in any form without the express written permission of NCCN.

PLEASE NOTE that use of this NCCN Content is governed by the End-User License Agreement, and you MAY NOT distribute this Content or use it with any artificial intelligence model or tool.
Printed by Máximo López Chenlo on 5/4/2026 6:21:12 PM. Copyright © 2026 National Comprehensive Cancer Network, Inc. All Rights Reserved.

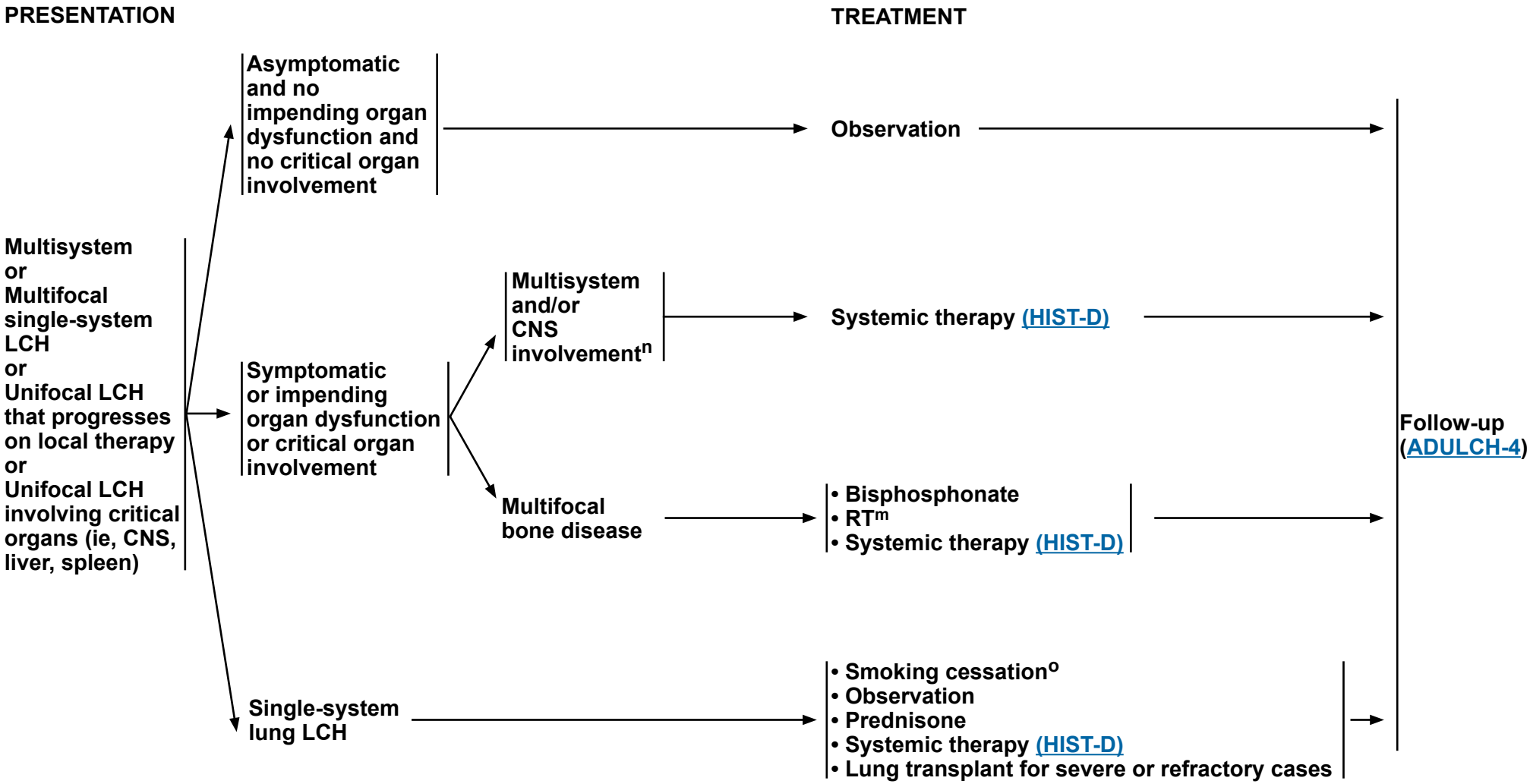

[m] Principles of Radiation Therapy (HIST-G).
[n] For neurodegenerative LCH, clinical findings may not be accompanied by imaging changes. Cognitive symptoms should be carefully evaluated and monitored, and early treatment should be considered if cognitive decline is evident.
[o] Provide resources for smoking cessation. See NCCN Guidelines for Smoking Cessation.

Note: All recommendations are category 2A unless otherwise indicated.

Version 2.2025, 11/21/25 © 2025 National Comprehensive Cancer Network® (NCCN®), All rights reserved. NCCN Guidelines® and this illustration may not be reproduced in any form without the express written permission of NCCN.

PLEASE NOTE that use of this NCCN Content is governed by the End-User License Agreement, and you MAY NOT distribute this Content or use it with any artificial intelligence model or tool.
Printed by Máximo López Chenlo on 5/4/2026 6:21:12 PM. Copyright © 2026 National Comprehensive Cancer Network, Inc. All Rights Reserved.

FOLLOW-UP

Treatment response assessment

Imaging of involved sites

- FDG-PET/CT scan vertex to toes (preferred) or contrast-enhanced CT/MRI
  - After 2–3 cycles of systemic therapy and at completion
  - After completion of surgical curettage
  - After RT[m]

Surveillance of patients on observation or in remission

- H&P and labs at least annually or more frequently as clinically indicated
- Imaging: FDG-PET/CT scan vertex to toes (preferred) or contrast-enhanced CT/MRI
  - No more than every 6 months for up to 2 years post completion of treatment
  - >2 years: no more than annually
  - For patients who are asymptomatic with a single-site bone lesion, imaging surveillance can potentially end after year 1, with continued tracking of symptoms
- Monitor PFTs every 6–12 months for up to 2 years for pulmonary LCH with further follow-up as clinically indicated
- Bone marrow evaluation in the presence of unexplained CBC abnormality (to rule out hemophagocytic lymphohistiocytosis, LCH, and/or associated myeloid neoplasm)
- For patients with:
  - BRAF inhibitors, regular skin examination and echocardiogram[p,q]
  - MEK inhibitors, regular skin examination, retinal examination, and echocardiogram[p,q]
  - Monitor every 1–2 years for pituitary hormone abnormalities

→

TREATMENT FOR RELAPSED/ REFRACTORY DISEASE

- Systemic therapy (HIST-D)
- If duration of response >1 year, consider same regimen; otherwise use a regimen not used for first-line therapy

→

See NCCN Guidelines for Survivorship

[m] Principles of Radiation Therapy (HIST-G).
[p] Principles of Supportive Care (HIST-E).
[q] Principles of Targeted Therapy (HIST-F).

Note: All recommendations are category 2A unless otherwise indicated.

Version 2.2025, 11/21/25 © 2025 National Comprehensive Cancer Network® (NCCN®), All rights reserved. NCCN Guidelines® and this illustration may not be reproduced in any form without the express written permission of NCCN.

PLEASE NOTE that use of this NCCN Content is governed by the End-User License Agreement, and you MAY NOT distribute this Content or use it with any artificial intelligence model or tool.
Printed by Máximo López Chenlo on 5/4/2026 6:21:12 PM. Copyright © 2026 National Comprehensive Cancer Network, Inc. All Rights Reserved.

WORKUP / EVALUATION[a]

ESSENTIAL:
- **H&P[b] with attention to common sites of involvement[c]**
- **Skeletal radiographic survey to detect skeletal lesions**
- **Laboratory evaluation[b]:**
  - **If unexplained cytopenia or anemia, consider bone marrow biopsy to assess for involvement with LCH, hemophagocytic lymphohistiocytosis, or other concurrent myeloid neoplasms**
- **Tissue biopsy[d] (PEDLCH-1A)**

USEFUL UNDER CERTAIN CIRCUMSTANCES, BASED ON SYMPTOMS OR ORGAN INVOLVEMENT:
- **Whole-body FDG-PET/CT or FDG-PET/MRI (vertex to toes) can be used if available, if a concern is present for multisystem LCH (MS-LCH) with risk organ involvement, or if disease reactivation is suspected**
- **Contrast-enhanced CT/MRI for assessment of other organ system involvement**
  - **Low-dose CT (LDCT) of the chest for suspected pulmonary and thymus LCH**
  - **US for suspected liver/spleen LCH**
  - **US for suspected lymph node involvement based on abnormal physical examination findings**
- **Contrast-enhanced brain MRI (white matter, pituitary, and sella turcica) in patients with a new onset isolated AVP deficiency[e]; CNS-risk bone lesions (mastoid and temporal bones; bones forming orbit); and MS-LCH with high-risk organ involvement to rule out pituitary gland involvement and neurodegenerative CNS LCH**
  - **MRI of the spine is optional and should be conducted if neurological symptoms are present or other imaging shows vertebral bone lesion**
- **Refer to other subspecialties (based on the clinical pattern): dental, dermatology, endocrinology, ear, nose, and throat (ENT), neurology, neuropsychology, neurosurgery, ophthalmology, orthopedics, psychosocial support, rehabilitation services**
- **If necessary for diagnosis confirmation, other testing may include: PFTs, echocardiogram, ERCP, electrical auditory brainstem response (E-ABR)**

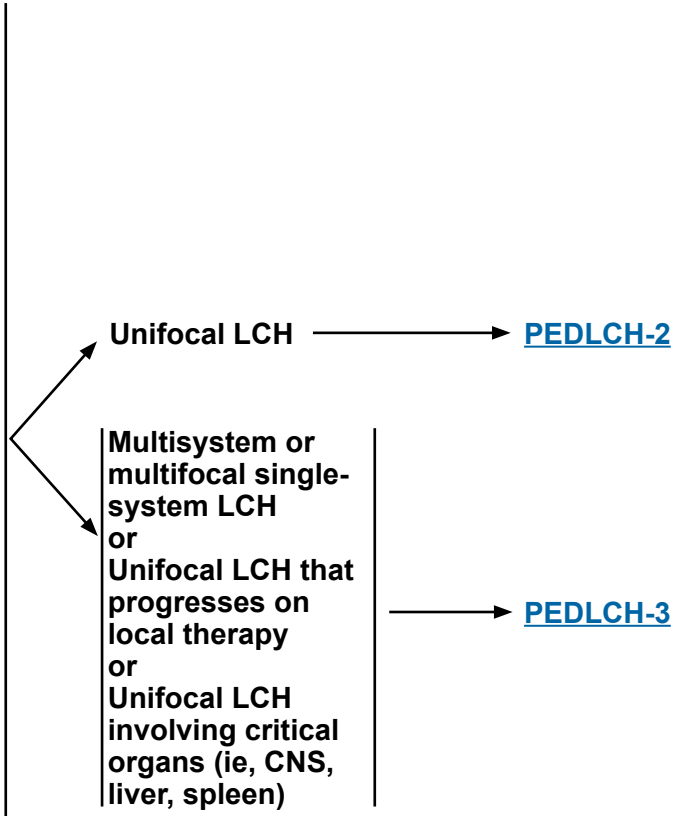

[a] See NCCN Guidelines for Adolescent and Young Adult (AYA) Oncology.
[b] Principles of Diagnostic Evaluation (HIST-A).
[c] Common sites of involvement include: bone, bone marrow, skin, GI system, lymph node, liver, spleen, oral mucosa, lung, and central nervous system (CNS). See Characteristic Features of Histiocytic Neoplasms (HIST-B).
[d] Principles of Pathology (HIST-C).
[e] Previously known as diabetes insipidus.

Note: All recommendations are category 2A unless otherwise indicated.

Version 2.2025, 11/21/25 © 2025 National Comprehensive Cancer Network® (NCCN®), All rights reserved. NCCN Guidelines® and this illustration may not be reproduced in any form without the express written permission of NCCN.

PLEASE NOTE that use of this NCCN Content is governed by the End-User License Agreement, and you MAY NOT distribute this Content or use it with any artificial intelligence model or tool.
Printed by Máximo López Chenlo on 5/4/2026 6:21:12 PM. Copyright © 2026 National Comprehensive Cancer Network, Inc. All Rights Reserved.

TISSUE BIOPSY ANALYSIS FOR LCH

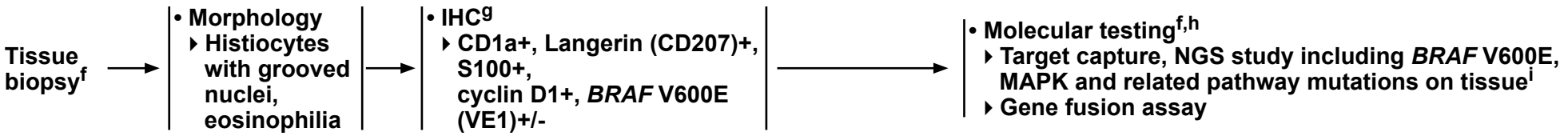

Immunophenotype key: +/-: positive or negative; +: positive; -: negative

[f] For patients with suspected LCH or histiocytosis and biopsy is not possible because of location or risk factors, mutational analysis of the peripheral blood is an option.
[g] At minimum, the IHC panel should include CD1a, S100, and Langerin; cyclin D1 and *BRAF* V600E (VE1, preferred antibody if possible).
[h] Molecular testing for somatic mutations and fusions can be performed in a stepwise manner or in parallel, depending on clinical need and institutional protocols. The frequency of suspected molecular lesions should drive the order of testing if a stepwise algorithm is chosen. Allele-specific PCR for *BRAF* V600E mutations can be the first step if *BRAF* V600E (VE1) IHC is not available or is equivocal. Targeted NGS panel testing should cover the common somatic mutations involving the MAPK pathway. RNA-based molecular panel including fusion testing should cover *BRAF*, *ALK*, *RET,* and *NTRK1* rearrangements. If there is a clinical concern for ALK-positive histiocytosis, ALK IHC and FISH using ALK break-apart probe should be performed.
[i] Fresh or paraffin-embedded tissue is used for NGS study; peripheral blood may be informative in multisystem disease. The NGS panel should cover the common MAPK pathway mutations (*BRAF, ARAF, NRAS, KRAS, MAP2K1/2)* and other related pathway mutations (eg, *PIK3CA*, *CSF1R)*.

Note: All recommendations are category 2A unless otherwise indicated.

Version 2.2025, 11/21/25 © 2025 National Comprehensive Cancer Network® (NCCN®), All rights reserved. NCCN Guidelines® and this illustration may not be reproduced in any form without the express written permission of NCCN.

PLEASE NOTE that use of this NCCN Content is governed by the End-User License Agreement, and you MAY NOT distribute this Content or use it with any artificial intelligence model or tool.
Printed by Máximo López Chenlo on 5/4/2026 6:21:12 PM. Copyright © 2026 National Comprehensive Cancer Network, Inc. All Rights Reserved.

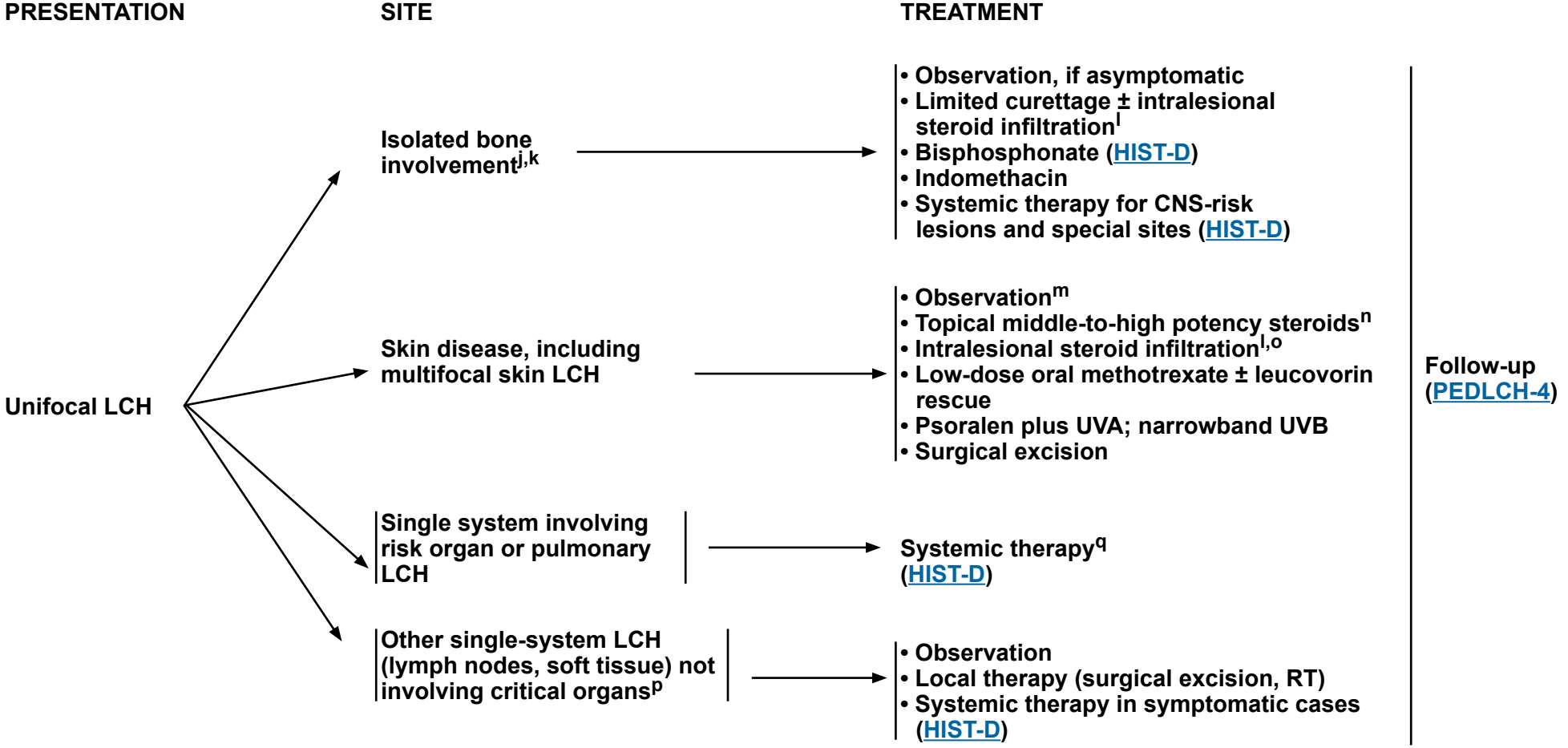

[j] For single site bone lesions with symptomatic extra-skeletal component, RT or systemic therapy may be warranted.
[k] Sentinel LN changes (enlargement, hypermetabolic activity on FDG-PET/CT) should not be regarded as another system involved, unless histologically confirmed by LN biopsy (CD1a+ histiocytes, characteristic immuno-architecture).
[l] Triamcinolone injection or equivalent corticosteroid.
[m] For small areas with no inflammatory changes.
[n] For larger areas or for lesions with inflammatory changes.
[o] For nodular lesions.
[p] Liver, spleen, BM, CNS, primary GI tract.
[q] Provide resources for smoking cessation if applicable. See NCCN Guidelines for Smoking Cessation.

Note: All recommendations are category 2A unless otherwise indicated.

Version 2.2025, 11/21/25 © 2025 National Comprehensive Cancer Network® (NCCN®), All rights reserved. NCCN Guidelines® and this illustration may not be reproduced in any form without the express written permission of NCCN.

PLEASE NOTE that use of this NCCN Content is governed by the End-User License Agreement, and you MAY NOT distribute this Content or use it with any artificial intelligence model or tool.
Printed by Máximo López Chenlo on 5/4/2026 6:21:12 PM. Copyright © 2026 National Comprehensive Cancer Network, Inc. All Rights Reserved.

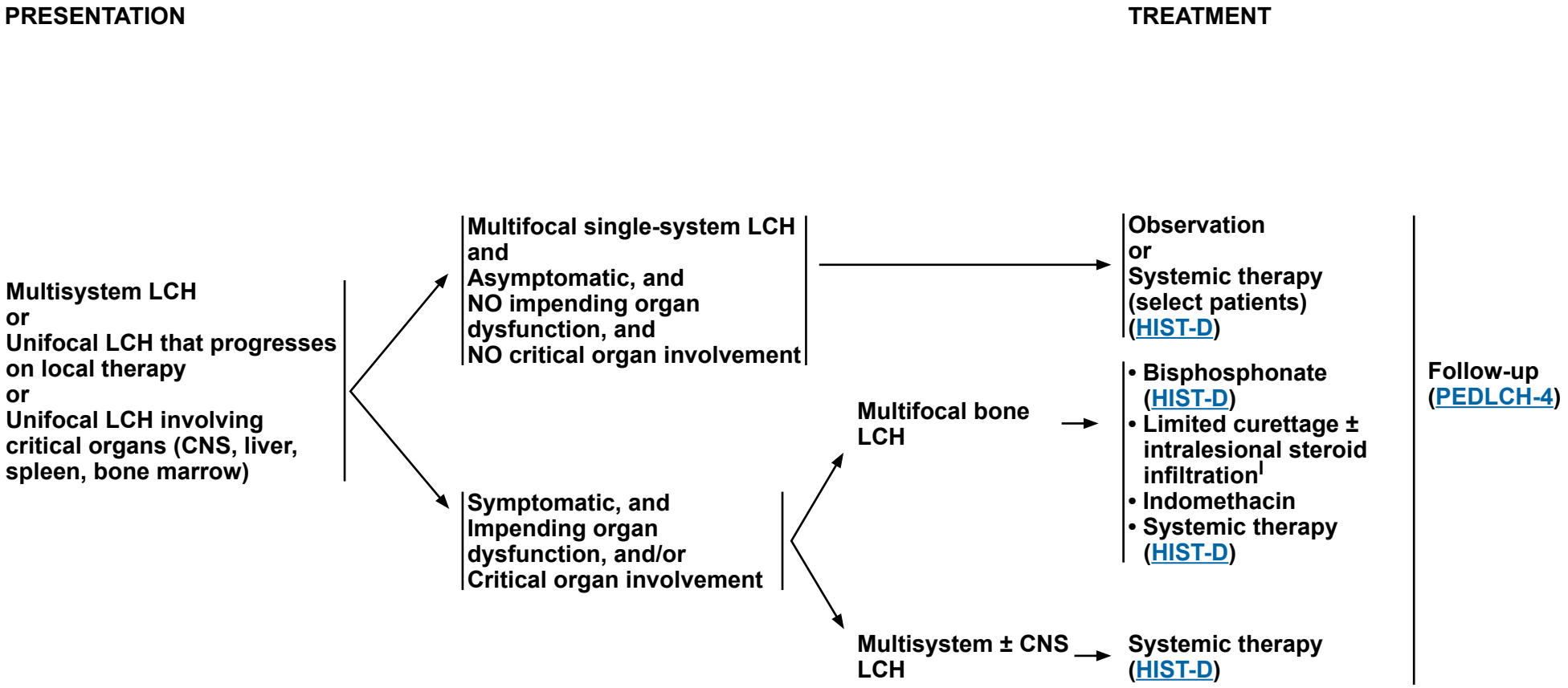

[I] Triamcinolone injection or equivalent corticosteroid.

Note: All recommendations are category 2A unless otherwise indicated.

Version 2.2025, 11/21/25 © 2025 National Comprehensive Cancer Network® (NCCN®), All rights reserved. NCCN Guidelines® and this illustration may not be reproduced in any form without the express written permission of NCCN.

PLEASE NOTE that use of this NCCN Content is governed by the End-User License Agreement, and you MAY NOT distribute this Content or use it with any artificial intelligence model or tool.
Printed by Máximo López Chenlo on 5/4/2026 6:21:12 PM. Copyright © 2026 National Comprehensive Cancer Network, Inc. All Rights Reserved.

FOLLOW-UP

Treatment response assessment

Imaging of involved sites

- Contrast-enhanced CT/MRI or consider skeletal radiographic survey to detect skeletal lesions or US for liver
  - After 2–3 cycles of systemic therapy and at completion
  - Immediately after completion of surgical curettage, and every 3 months until full evidence of the healed bone
  - After RT

Surveillance of patients on observation or in remission

- H&P and labs at least annually or more frequently as clinically indicated (hormonal status, pituitary gland and adrenal gland function)
- Imaging: contrast-enhanced CT/MRI or skeletal radiographic survey for reactivation
  - No more than every 6 months for up to 2 years post completion of treatment in the absence of a clinical concern of recurrence
  - >2 years: no more than annually
  - For patients who are asymptomatic with a single-site bone lesion, imaging surveillance can potentially end after year 1, with continued tracking of symptoms
- Annual contrast-enhanced brain MRI for patients with CNS-risk and high-risk lesions for 5 years and as clinically indicated thereafter
- Monitor PFTs every 6–12 months for up to 2 years for pulmonary LCH with further follow up as clinically indicated
- Bone marrow evaluation for patients with prior BM involvement or in the presence of unexplained CBC abnormality (to rule out associated myeloid neoplasm)
  - In the rare case of BM involvement, repeat biopsy post-therapy to ensure it has been resolved
- For patients with:
  - BRAF inhibitors, regular skin examination and echocardiogram
  - MEK inhibitors, regular skin examination, retinal examination, and echocardiogram
- Monitor every 1–2 years for pituitary hormone abnormalities
- Continue subspecialty involvement as indicated

TREATMENT FOR RELAPSED/ REFRACTORY DISEASE

→ Systemic therapy (HIST-D)
- If duration of response >1 year, consider same regimen; otherwise use a regimen not used for first-line or consider a re-biopsy

→ See NCCN Guidelines for Survivorship

Note: All recommendations are category 2A unless otherwise indicated.

Version 2.2025, 11/21/25 © 2025 National Comprehensive Cancer Network® (NCCN®), All rights reserved. NCCN Guidelines® and this illustration may not be reproduced in any form without the express written permission of NCCN.

PLEASE NOTE that use of this NCCN Content is governed by the End-User License Agreement, and you MAY NOT distribute this Content or use it with any artificial intelligence model or tool.
Printed by Máximo López Chenlo on 5/4/2026 6:21:12 PM. Copyright © 2026 National Comprehensive Cancer Network, Inc. All Rights Reserved.

WORKUP / EVALUATION[a]

ESSENTIAL:
- **H&P[b] with attention to common sites of involvement[c]**
- **Whole-body FDG-PET/CT scan including distal extremities (vertex to toes)**
- **Laboratory evaluation[b]**
  - **If unexplained CBC abnormality, consider bone marrow biopsy to assess for hemophagocytic lymphohistiocytosis, ECD, and/or associated myeloid neoplasm[d]**
- **Tissue biopsy[e] (ECD-1A)**

USEFUL UNDER CERTAIN CIRCUMSTANCES, BASED ON SYMPTOMS OR ORGAN INVOLVEMENT:
- **CT of the following:**
  - **chest, abdomen, and pelvis with contrast[f]**
  - **sinuses with contrast**
  - **chest (high-resolution)**
- **MRI with and without contrast for the following:**
  - **brain**
  - **orbit**
  - **spine**
  - **sella turcica ± pituitary (if AVP deficiency[g] suspected)**
- **PFTs (especially for suspected pulmonary Erdheim-Chester disease [ECD])**
- **TTE**
- **Renal artery US**
- **Testicular US**
- **Technetium-99m (Tc-99m) methylene diphosphonate (MDP) bone scintigraphy**

→ **Treatment (ECD-2)**

[a] Adapted with permission from Goyal G, et al. Blood 2020;135:1929-1945.
[b] Please see Principles of Diagnostic Evaluation (HIST-A) for details on H&P and laboratory evaluation.
[c] Common sites of involvement include: long bones (bilateral and symmetric diaphyseal and metaphyseal osteosclerosis with subchondral sparing); orbits (retro-orbital mass with exophthalmos; xanthelasma); CNS (pituitary gland, posterior fossa); lungs (interstitial changes); vascular (periaortic infiltrate; pericardium; right atrium); and retroperitoneal/perinephric or "hairy kidney" (mesentery). See Characteristic Features of Histiocytic Neoplasms (HIST-B).
[d] See NCCN Guidelines for Myelodysplastic Syndromes or NCCN Guidelines for Myeloproliferative Neoplasms.
[e] Principles of Pathology (HIST-C).
[f] The presence of hairy kidney is highly suggestive of ECD and is present in 50% to 68% of patients. Periarterial infiltration involving the thoracic or abdominal aorta and other vessels is present in 56% to 85% of patients with ECD. Goyal G, et al. Mayo Clin Proc 2019;94:2054-2071.
[g] Previously known as diabetes insipidus.

Note: All recommendations are category 2A unless otherwise indicated.

Version 2.2025, 11/21/25 © 2025 National Comprehensive Cancer Network® (NCCN®), All rights reserved. NCCN Guidelines® and this illustration may not be reproduced in any form without the express written permission of NCCN.

PLEASE NOTE that use of this NCCN Content is governed by the End-User License Agreement, and you MAY NOT distribute this Content or use it with any artificial intelligence model or tool.
Printed by Máximo López Chenlo on 5/4/2026 6:21:12 PM. Copyright © 2026 National Comprehensive Cancer Network, Inc. All Rights Reserved.

TISSUE BIOPSY ANALYSIS FOR ECD

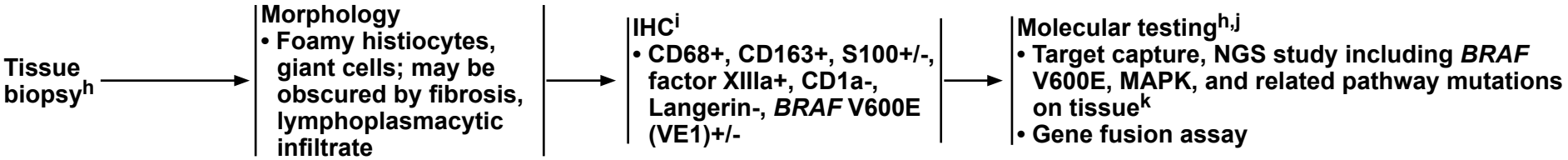

Immunophenotype key: +/-: positive or negative; +: positive; -: negative

[h] For patients with suspected ECD or histiocytosis and biopsy is not possible because of location or risk factors, mutational analysis of the peripheral blood is an option. Janku F, et al. Mol Cancer Ther 2019;18:1149-1157.

[i] At minimum, the IHC panel recommended should include CD68 or CD163, factor XIIIa, S100, CD1a, and *BRAF* V600E (VE1, preferred antibody if possible).

[j] Molecular testing for somatic mutations and fusions can be performed in a stepwise manner or in parallel, depending on clinical need and institutional protocols. The frequency of suspected molecular lesions should drive the order of testing if a stepwise algorithm is chosen. Allele-specific PCR for *BRAF* V600E mutations can be the first step if *BRAF* V600E (VE1) IHC is not available or is equivocal. Targeted NGS panel testing should cover the common somatic mutations involving the MAPK pathway. RNA-based molecular panel including fusion testing should cover *BRAF*, *ALK*, *RET,* and *NTRK1* rearrangements. If there is clinical concern for *ALK*-positive histiocytosis, ALK IHC and FISH using ALK break-apart probe should be performed.

[k] Fresh or paraffin-embedded tissue is used for the NGS study; peripheral blood testing may be informative in multisystem disease. The NGS panel should cover the common MAPK pathway mutations (ie, *BRAF, ARAF, NRAS, KRAS, MAP2K1/2)* and other related pathway mutations (eg, *PIK3CA*, *CSF1R)*. If clinically indicated in cases without the usual MAPK pathway mutations, FISH for *BRAF*, *ALK*, *RET,* or *NTRK1* fusions may be performed.

Note: All recommendations are category 2A unless otherwise indicated.

Version 2.2025, 11/21/25 © 2025 National Comprehensive Cancer Network® (NCCN®), All rights reserved. NCCN Guidelines® and this illustration may not be reproduced in any form without the express written permission of NCCN.

PLEASE NOTE that use of this NCCN Content is governed by the End-User License Agreement, and you MAY NOT distribute this Content or use it with any artificial intelligence model or tool.
Printed by Máximo López Chenlo on 5/4/2026 6:21:12 PM. Copyright © 2026 National Comprehensive Cancer Network, Inc. All Rights Reserved.

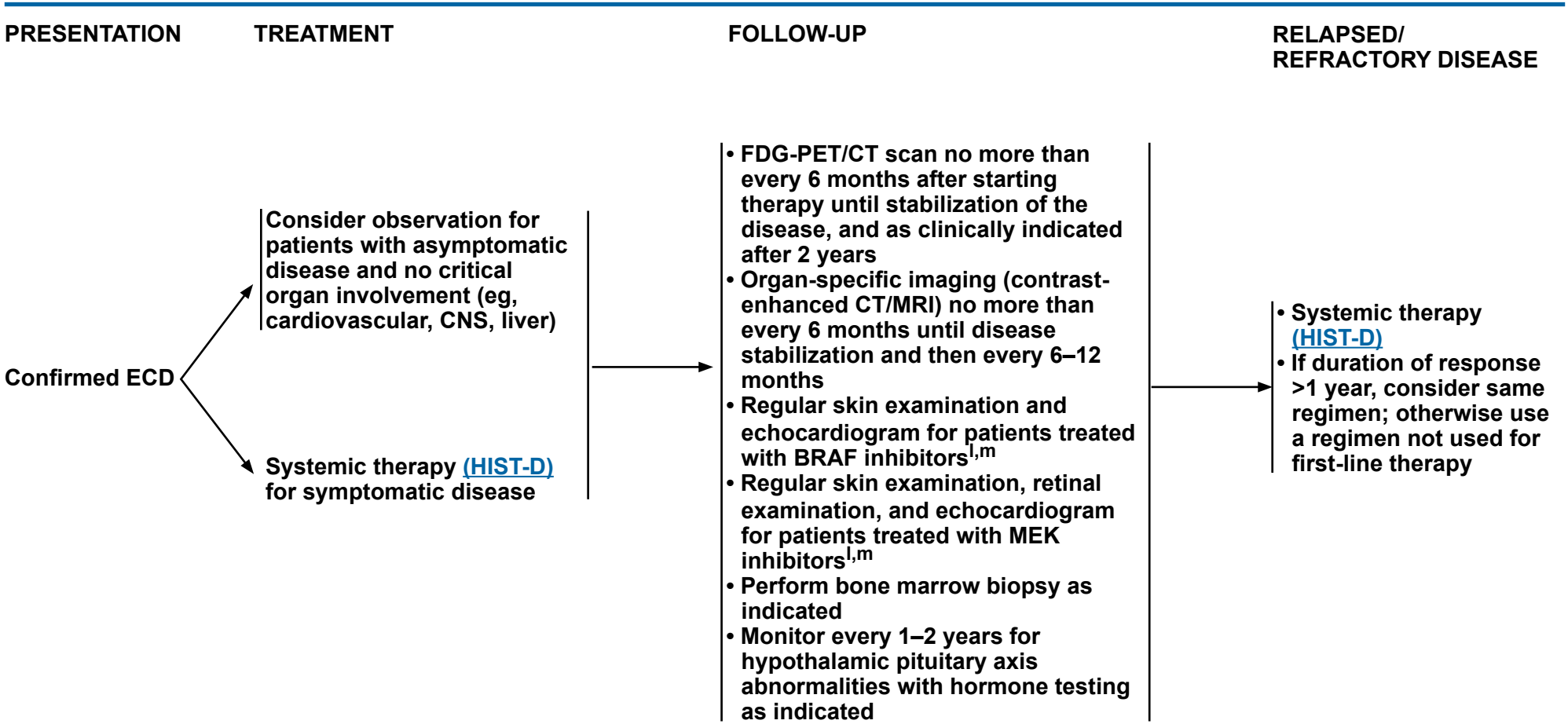

[l] Principles of Targeted Therapy (HIST-F).
[m] Principles of Supportive Care (HIST-E).

Note: All recommendations are category 2A unless otherwise indicated.

Version 2.2025, 11/21/25 © 2025 National Comprehensive Cancer Network® (NCCN®), All rights reserved. NCCN Guidelines® and this illustration may not be reproduced in any form without the express written permission of NCCN.

PLEASE NOTE that use of this NCCN Content is governed by the End-User License Agreement, and you MAY NOT distribute this Content or use it with any artificial intelligence model or tool.
Printed by Máximo López Chenlo on 5/4/2026 6:21:12 PM. Copyright © 2026 National Comprehensive Cancer Network, Inc. All Rights Reserved.

WORKUP / EVALUATION[a]

ESSENTIAL:
- **H&P[b] with attention to common sites of involvement[c]**
- **Whole-body FDG-PET/CT scan including distal extremities (vertex to toes)**
- **Laboratory evaluation[b]**
- **Tissue biopsy[d] (RDD-1A)**

USEFUL UNDER CERTAIN CIRCUMSTANCES, BASED ON SYMPTOMS OR ORGAN INVOLVEMENT:
- **CT of the following:**
  - **chest, abdomen, and pelvis with contrast**
  - **sinuses with contrast**
  - **chest (high-resolution)**
- **MRI with and without contrast for the following:**
  - **brain**
  - **orbit**
  - **spine**
  - **sella turcica ± pituitary (if AVP deficiency[e] suspected)**
- **PFTs (especially for suspected pulmonary Rosai-Dorfman disease [RDD])**
- **TTE**
- **Thyroid US**
- **Testicular US**

→ **Treatment (RDD-2)**

[a] Adapted with permission from Abla O, et al. Blood 2018;131:2877-2890.
[b] Please see Principles of Diagnostic Evaluation (HIST-A) for details on H&P and laboratory evaluation.
[c] Common sites of involvement include: peripheral lymphadenopathy, subcutaneous nodules, and extranodal sites (ie, skin, soft tissue, upper respiratory tract, bone, retroperitoneum, orbits, spleen). See Characteristic Features of Histiocytic Neoplasms (HIST-B).
[d] Principles of Pathology (HIST-C).
[e] Previously known as diabetes insipidus.

Note: All recommendations are category 2A unless otherwise indicated.

Version 2.2025, 11/21/25 © 2025 National Comprehensive Cancer Network® (NCCN®), All rights reserved. NCCN Guidelines® and this illustration may not be reproduced in any form without the express written permission of NCCN.

PLEASE NOTE that use of this NCCN Content is governed by the End-User License Agreement, and you MAY NOT distribute this Content or use it with any artificial intelligence model or tool.
Printed by Máximo López Chenlo on 5/4/2026 6:21:12 PM. Copyright © 2026 National Comprehensive Cancer Network, Inc. All Rights Reserved.

TISSUE BIOPSY ANALYSIS FOR RDD

Tissue biopsy[f] →

Morphology
- **Histiocytes with round nuclei, central nucleoli, emperipolesis; plasmacytosis**

→

IHC[g]
- **S100+, CD68+, CD163+, cyclin D1+/-, CD1a-, Langerin-, OCT2+, *BRAF* V600E (VE1)**

→

Molecular testing[f,h]
- **Target capture, NGS study including *BRAF* V600E, MAPK, and related pathway mutations on tissue[i]**
- **Gene fusion assay**
- **Germline mutations (optional)[i]**

Immunophenotype key: +/-: positive or negative; +: positive; -: negative

[f] For patients with suspected RDD or histiocytosis and biopsy is not possible because of location or risk factors, liquid biopsy for mutational analysis in the peripheral blood is an option. Janku F, et al. Mol Cancer Ther 2019;18:1149-1157.

[g] At minimum, the IHC panel recommended should include CD68 or CD163, S100, CD1a; cyclin D1 and *BRAF* V600E (VE1, preferred antibody if possible). Of caution, cyclin D1 could also be positive or detected in concurrent lymphocytic or histiocytic neoplasm. VE1 is the preferred antibody for *BRAF* V600E testing if possible. A novel study showed that OCT2 IHC might be helpful, if clinically indicated, in select cases to confirm a suspected diagnosis of RDD, together with other common diagnostic markers. Ravindran A, et al. Am J Surg Pathol 2021;45:35-44.

[h] NGS sequencing studies are performed if clinically indicated, which may reveal mutations in the MAPK pathway (eg, KRAS, MAP2K1/2) with or without additional somatic mutations also seen in myeloid neoplasia

[i] If a familial RDD is suspected, germline mutations in *SLC29A3* should be considered. Another germline gene mutation involving the *Fas* gene *TNFRSF6* is found in 40% of patients with RDD who had an autoimmune lymphoproliferative syndrome (ALPS) type Ia.

Note: All recommendations are category 2A unless otherwise indicated.

Version 2.2025, 11/21/25 © 2025 National Comprehensive Cancer Network® (NCCN®), All rights reserved. NCCN Guidelines® and this illustration may not be reproduced in any form without the express written permission of NCCN.

PLEASE NOTE that use of this NCCN Content is governed by the End-User License Agreement, and you MAY NOT distribute this Content or use it with any artificial intelligence model or tool.
Printed by Máximo López Chenlo on 5/4/2026 6:21:12 PM. Copyright © 2026 National Comprehensive Cancer Network, Inc. All Rights Reserved.

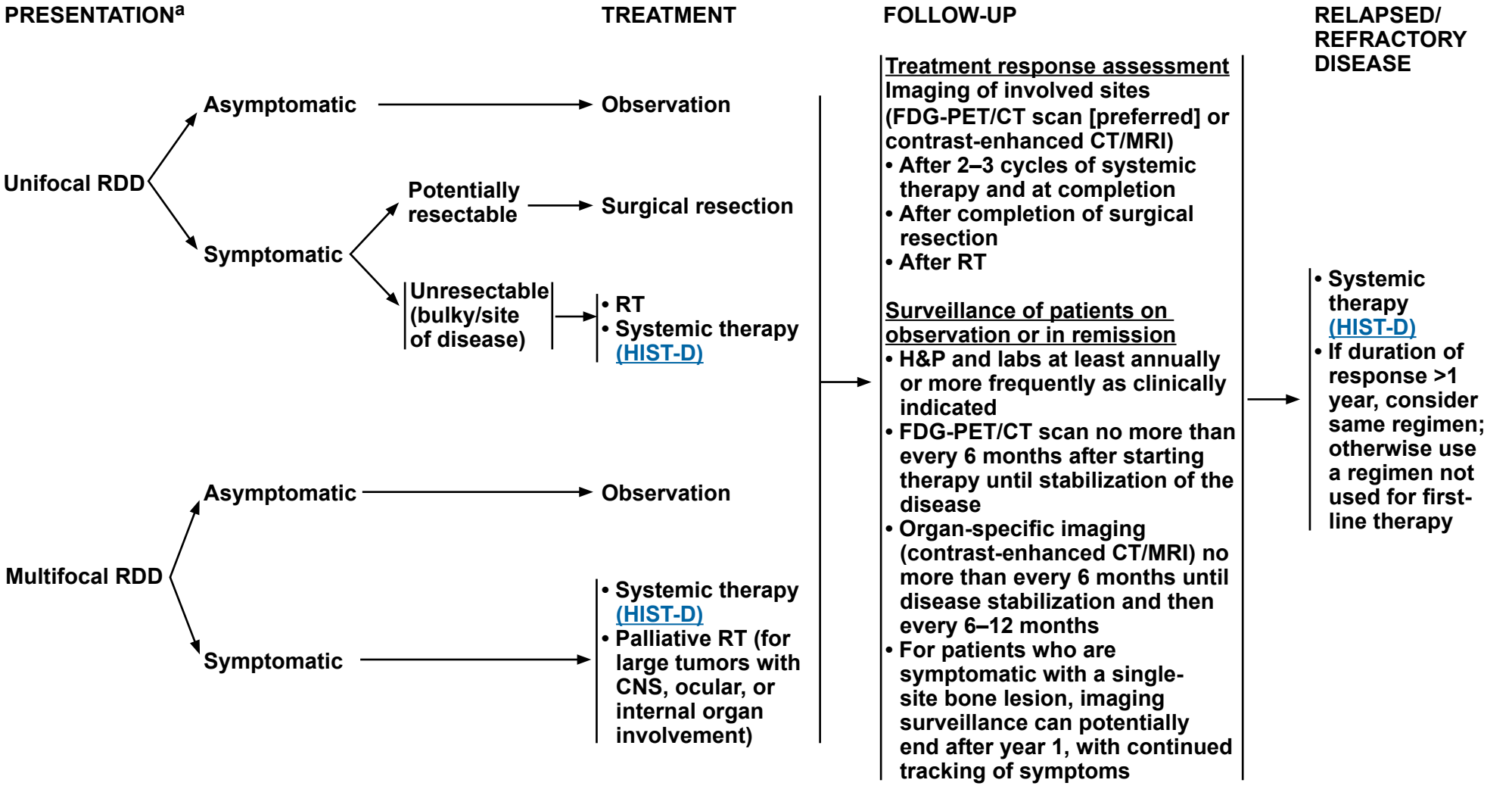

[a] Adapted with permission from Abla O, et al. Blood 2018;131:2877-2890.

Note: All recommendations are category 2A unless otherwise indicated.

Version 2.2025, 11/21/25 © 2025 National Comprehensive Cancer Network® (NCCN®), All rights reserved. NCCN Guidelines® and this illustration may not be reproduced in any form without the express written permission of NCCN.

PLEASE NOTE that use of this NCCN Content is governed by the End-User License Agreement, and you MAY NOT distribute this Content or use it with any artificial intelligence model or tool.
Printed by Máximo López Chenlo on 5/4/2026 6:21:12 PM. Copyright © 2026 National Comprehensive Cancer Network, Inc. All Rights Reserved.

PRINCIPLES OF DIAGNOSTIC EVALUATION

Medical History and Physical Examination:

- Constitutional: fevers, night sweats, fatigue, headache, myalgias, weight loss
- HEENT (head, eyes, ears, nose, and throat): double or decreased vision, blurry vision, decreased hearing, mass, lymphadenopathy, retro-orbital pain, xanthelasma, exophthalmos, eyelids/lacrimal swelling, proptosis, nasal obstruction, epistaxis, hyposmia, oral lesions or pain, dysmorphic facies, and enlarged tongue or tonsils
- Cardiovascular: dyspnea, orthopnea, hypertension, irregular pulse, bradycardia, tachycardia, cardiomegaly, murmurs
- Pulmonary: dyspnea, cough, hemoptysis, chest pain, diminished aeration, rales, crackles, pneumothorax; evaluate smoking history[a]
- Musculoskeletal: bone pain, back pain, muscle pain, joint pain, osseous mass
- Lymphatic: lymphadenopathy
- Abdominal/gastrointestinal (GI): diarrhea, melena, flank mass, hepatosplenomegaly, abdominal pain, constipation, hematochezia
- Genital: testicular or epididymal mass or enlargement
- Skin: erythematous rash, subcutaneous nodules, attention to ear canals, periorbital region, perineum, axillae, inguinal region, xanthelasma, pruritus, papules, plaques
- Thoracic: diminished lung aeration, rales, axillary nodes, breast mass
- Renal: hematuria, flank pain
- Endocrine: polydipsia/polyuria, gynecomastia, decreased libido, weight changes, appetite changes, cold intolerance, constipation
- Neurologic: headaches, ataxia, dysarthria, seizures, cognitive decline, disconjugate gaze, cranial nerve palsies, ataxic or magnetic gait, sensory or motor impairment, hemiparesis, hyperreflexia, dysphagia, limb or facial weakness, sensory changes, hearing impairment
- Psychiatric: depression, anxiety, disinhibition, inappropriate laughing or crying, pseudobulbar affect
- For RDD: history of autoimmune disease, autoimmune lymphoproliferative syndrome (ALPS), malignancy, LCH, or another histiocytic disorder
- For familial RDD: family history (parents who are consanguineous, autoimmune disease, Turkish/Pakistani or Middle Eastern ancestry)

Laboratory Evaluation:

- CBC with differential (ADULCH-1A or PEDLCH-1A or ECD-1A or RDD-1A)
- Comprehensive metabolic panel including liver and kidney function assessments
- For anemia: Coombs test, haptoglobin, reticulocyte count, and blood smear
- C-reactive protein (CRP)
- Morning urine and serum osmolality
- Morning serum cortisol with adrenocorticotropic hormone (ACTH)
- Follicle-stimulating hormone (FSH)/luteinizing hormone (LH) with testosterone (males) and estradiol (females)
- Thyroid-stimulating hormone (TSH) and free T4

[a] Provide resources for smoking cessation. See NCCN Guidelines for Smoking Cessation.

Continued

Note: All recommendations are category 2A unless otherwise indicated.

Version 2.2025, 11/21/25 © 2025 National Comprehensive Cancer Network® (NCCN®), All rights reserved. NCCN Guidelines® and this illustration may not be reproduced in any form without the express written permission of NCCN.

PLEASE NOTE that use of this NCCN Content is governed by the End-User License Agreement, and you MAY NOT distribute this Content or use it with any artificial intelligence model or tool.
Printed by Máximo López Chenlo on 5/4/2026 6:21:12 PM. Copyright © 2026 National Comprehensive Cancer Network, Inc. All Rights Reserved.

PRINCIPLES OF DIAGNOSTIC EVALUATION

Laboratory Evaluation: (continued)
- **Prolactin and insulin-like growth factor 1 (IGF-1)**
- **Lumbar puncture (for brain lesions inaccessible to biopsy)**
- **Bone marrow aspirate/biopsy (ADULCH-1A or PEDLCH-1A or ECD-1A or RDD-1A)**
- **For RDD: Serum immunoglobulins**
- **For RDD: ALPS panel, antinuclear antibody (ANA), antineutrophil cytoplasmic antibodies (ANCA), rheumatoid factor (RF), HLA-B27: if autoimmune disease is suspected and based on clinical findings**
- **For pediatric LCH: Coagulation panel, plasma and urine osmolality, urinalysis/urine specific gravity**

Subspecialty Consultations as Needed:
- **Cardiology**
- **Pulmonary**
- **Neurology**
- **Endocrinology, especially for pediatric LCH to evaluate pituitary gland involvement**
- **Dermatology during BRAF or MEK inhibitor therapy[b,c]**
- **Ophthalmology during MEK inhibitor therapy[b,c]**
- **Dental/periodontal**
- **Smoking cessation[a]**
- **Palliative medicine[d]**

[a] Provide resources for smoking cessation. See NCCN Guidelines for Smoking Cessation.
[b] Principles of Targeted Therapy (HIST-F).
[c] Principles of Supportive Care (HIST-E).
[d] NCCN Guidelines for Palliative Care.

Note: All recommendations are category 2A unless otherwise indicated.

Version 2.2025, 11/21/25 © 2025 National Comprehensive Cancer Network® (NCCN®), All rights reserved. NCCN Guidelines® and this illustration may not be reproduced in any form without the express written permission of NCCN.

PLEASE NOTE that use of this NCCN Content is governed by the End-User License Agreement, and you MAY NOT distribute this Content or use it with any artificial intelligence model or tool.
Printed by Máximo López Chenlo on 5/4/2026 6:21:12 PM. Copyright © 2026 National Comprehensive Cancer Network, Inc. All Rights Reserved.

CHARACTERISTIC FEATURES OF HISTIOCYTIC NEOPLASMS[a]

Feature	ECD	LCH	RDD
Bones	Pathognomonic long-bone osteosclerosis at the metadiaphysis	Osteolytic lesions including skull	Cortex-based osteolytic lesions most common
Nervous system	Brainstem/cerebellum masses; cerebral white matter enhancement; dural and pituitary stalk thickening	MRI with globus pallidus/dentate nucleus T1 hyperintensity; brainstem/cerebellum T2 hyperintensity; dural lesion from intracranial extension of skull lesion; pituitary stalk thickening	Isolated dural or parenchymal lesion
Endocrine	AVP deficiency[b] may present years before diagnosis of ECD	AVP deficiency[b] may present years before diagnosis of LCH	AVP deficiency[b] never reported
Respiratory	Mediastinal infiltration; pleural, septal, and maxillary sinus thickening	Mostly seen in people who smoke; HRCT shows pulmonary nodules in the early stage, cysts in the later stage	Primarily involving large airways and sinuses; rarely interstitial pulmonary or sinus thickening; pleural or pulmonary nodule
Dermatologic	Xanthelasma-like lesions around eyes, face, neck, inguinal folds	Papular rash; rarely subcutaneous nodules or xanthelasma-like lesions	Subcutaneous nodules, may be seen as macular or papular rash that varies in color
Cardiac	Right atrial and atrioventricular groove infiltration; pericardial and myocardial infiltration seen on cardiac MRI	Rarely reported	Infiltration of the right atrium, interatrial septum, and left ventricle
Arterial	Periaortic infiltration “coated aorta”; infiltration of the supra-aortic trunk branches, visceral arteries, renal artery stenosis, coronary arteries	Rarely reported	Infiltration of the periaortic and carotid sheath

[a] Adapted with permission from Goyal G, et al. Mayo Clin Proc 2019;94:2054-2071.
[b] Previously known as diabetes insipidus.

Continued

Note: All recommendations are category 2A unless otherwise indicated.

Version 2.2025, 11/21/25 © 2025 National Comprehensive Cancer Network® (NCCN®), All rights reserved. NCCN Guidelines® and this illustration may not be reproduced in any form without the express written permission of NCCN.

PLEASE NOTE that use of this NCCN Content is governed by the End-User License Agreement, and you MAY NOT distribute this Content or use it with any artificial intelligence model or tool.
Printed by Máximo López Chenlo on 5/4/2026 6:21:12 PM. Copyright © 2026 National Comprehensive Cancer Network, Inc. All Rights Reserved.

CHARACTERISTIC FEATURES OF HISTIOCYTIC NEOPLASMS[a]

Feature	ECD	LCH	RDD
Retroperitoneum, including kidneys	Perinephric infiltration “hairy kidneys” with extension to renal pelvis and ureters causing renal failure; adrenal infiltration	Rarely reported	Commonly hilar masses; subcapsular infiltration; rarely perinephric coating
Lymph nodes	Never reported	Rarely isolated	May present as isolated or generalized lymphadenopathy
Orbits	Orbital masses	Never reported	Orbital masses, sometimes involving the optic nerve

[a] Adapted with permission from Goyal G, et al. Mayo Clin Proc 2019;94:2054-2071.

Note: All recommendations are category 2A unless otherwise indicated.

Version 2.2025, 11/21/25 © 2025 National Comprehensive Cancer Network® (NCCN®), All rights reserved. NCCN Guidelines® and this illustration may not be reproduced in any form without the express written permission of NCCN.

PLEASE NOTE that use of this NCCN Content is governed by the End-User License Agreement, and you MAY NOT distribute this Content or use it with any artificial intelligence model or tool.
Printed by Máximo López Chenlo on 5/4/2026 6:21:12 PM. Copyright © 2026 National Comprehensive Cancer Network, Inc. All Rights Reserved.

PRINCIPLES OF PATHOLOGY

General Principles

- LCH, ECD, and RDD pose a diagnostic challenge given their rarity, their overlap with each other, reactive processes, and co-occurrence with other hematologic or non-hematologic neoplasms.
- Numerous site-specific mimics of histiocytoses exist due to relatively nonspecific appearance and immunophenotype, such as granular cell tumor, giant cell tumors of the bone and soft tissue, xanthogranulomas, multicentric reticulohistiocytosis, and immunoglobulin G4 (IgG4)-related disease. Manifestations may also vary by site.[1,2]
- Comprehensive immunophenotyping should be performed including S100, CD1a, Langerin (CD207), CD68 and/or CD163, cyclin D1, *BRAF* V600E (VE1), factor XIIIa, and, if indicated, *ALK* and fascin. Discriminatory markers for carcinoma, melanoma, lymphoma, sarcoma, and other suspected disorders are useful for differential diagnoses. Cyclin D1 IHC can be helpful to distinguish LCH from reactive Langerhans cell collections and has also been reported to be positive in RDD.[3-5]
- ALK IHC may be considered, as *ALK*+ histiocytosis may carry a targetable *ALK* rearrangement.[6,7]
- It is recommended to perform molecular mutation profiling to aid in confirmation of a clonal Langerhans or histiocytic process and to identify potential prognostically relevant mutations or therapeutic targets. Correlation with clinical presentation and imaging findings is crucial for accurate diagnosis. Tissue diagnosis should be confirmed by pathologists with expertise in site-specific histiocytic lesions (eg, hematopathology, dermatopathology, pulmonary pathology, neuropathology).[8]
- In patients with unexplained cytopenias, bone marrow biopsy should be considered due to possible concomitant bone marrow processes, such as hemophagocytic lymphohistiocytosis or myeloid neoplasia (ie, myelodysplastic syndrome [MDS], myeloproliferative neoplasms [MPN], chronic myelomonocytic leukemia [CMML]).[9-15]
- For LCH and ECD, molecular testing for somatic mutations and fusions can be performed in a stepwise manner or in parallel, depending on clinical need and institutional protocols. The frequency of suspected molecular lesions should drive the order of testing if a stepwise algorithm is chosen. Allele-specific polymerase chain reaction (PCR) for *BRAF* V600E (VE1) mutations can be the first step if *BRAF* V600E (VE1) IHC is not available or is equivocal.[16] Somatic mutation NGS panel testing should cover the common MAPK pathway mutations. RNA-based molecular panel fusion testing should cover *BRAF*, *ALK*, *RET,* and *NTRK1* rearrangements. If there is clinical concern for *ALK* rearrangement, or if fusion panel testing is not available, ALK IHC and fluorescence in situ hybridization (FISH) studies may be performed. Repeat molecular testing in negative cases, potentially using a different tissue sample.

Langerhans Cell Histiocytosis

- LCH is an abnormal proliferation of Langerhans-type cells with frequent driver mutations involving the MAPK pathway (RAS-RAF-MEK-ERK).
- Histopathologic features include cells with oval or twisted, grooved, or lobulated nuclei, finely granular chromatin, inconspicuous nucleoli, and abundant cytoplasm; these cells frequently have admixed eosinophils and histiocytes, including multinucleated forms, but not usually plasma cell rich. Ki-67 is variable.
- Langerhans cells show immunoreactivity for S100, CD1a, and Langerin (CD207).
- Reactive Langerhans cell infiltrates may mimic LCH; by IHC, expression of cyclin D1 (BCL1) and *BRAF* V600E (VE1 clone) support LCH.[6] VE1 staining is not 100% sensitive or specific, and concurrent molecular testing is recommended.
- Activating signaling pathway mutations found in LCH include *BRAF* V600E, *BRAF* indels, *MAP2K1/2, N/KRAS*, and *ARAF*. Kinase fusions (ie, *BRAF, ALK, RET, NTRK1*) and mutations in the PI3K-AKT-mTOR pathway have been reported in LCH as well.[17-19] Concomitant panel testing for *BRAF* V600E (VE1) and other MAPK pathway mutations is recommended.[20,21]
- Approximately 50% of pediatric LCH cases demonstrate a *BRAF* V600E mutation. In those with non-*BRAF* V600E-mutated LCH, NGS revealed the prevalence of other somatic mutations: *MAP2K1* exon 2 or 3 mutations (42%), *BRAF* exon 12 deletions and duplications (32%), other *BRAF* V600 codon mutation (4%), and non-MAPK pathway genes (4%).[22]

References on HIST-C 5 of 6
Continued

Note: All recommendations are category 2A unless otherwise indicated.

Version 2.2025, 11/21/25 © 2025 National Comprehensive Cancer Network® (NCCN®), All rights reserved. NCCN Guidelines® and this illustration may not be reproduced in any form without the express written permission of NCCN.

PLEASE NOTE that use of this NCCN Content is governed by the End-User License Agreement, and you MAY NOT distribute this Content or use it with any artificial intelligence model or tool.
Printed by Máximo López Chenlo on 5/4/2026 6:21:12 PM. Copyright © 2026 National Comprehensive Cancer Network, Inc. All Rights Reserved.

PRINCIPLES OF PATHOLOGY

Erdheim-Chester Disease

- Histopathologic features include foamy (xanthomatous) histiocytes, including Touton cells in a background of spindled cells and fibrosis. Reactive lymphocytes, plasma cells, and neutrophils are also often present. Typical histologic findings vary by site.[8] For example, bone lesions may be masked by significant fibrosis, including, in some cases, storiform fibrosis. In CNS and lung, the lesional histiocytes are non-lipidized, with eosinophilic cytoplasm, and lack the typical inflammatory infiltrate. In skin, the typical xanthomatous histiocytes are common but can be diffuse or interstitial and relatively subtle. In the retroperitoneum, findings are usually xanthomatous but sometimes extensively fibrotic, and can be associated with increased IgG4+ plasma cells meeting criteria for IgG4-related disease. Finally, in cardiac tissues, diffuse infiltrates of xanthomatous histiocytes may be observed.
- The neoplastic cells show immunoreactivities for some histiocytic markers (eg, CD68w, CD163, fascin, factor XIIIa). They are negative for CD1a and Langerin (CD207) and can be dim S100+.
- Activating signaling pathway mutations found in ECD are similar to those found in LCH, though *PIK3CA* activating mutation is more common in ECD. *BRAF* V600E mutation has been detected in about 50% of patients with ECD. Kinase fusions (ie, *BRAF*, *ALK*, *RET, NTRK1*) and *CSF1R* mutations have been reported rarely as well.[17,19,23] The revised histiocytic classification recommends classification of all "JXG" with activating MAPK pathway mutations (*BRAF, NRAS, KRAS, MAP2K1/2*) as ECD.[24,25]

Rosai-Dorfman Disease

- RDD comprises a heterogeneous group of clinical presentations that can be associated with familial, autoimmune, or malignant process. Classical sporadic RDD shows bilateral painless massive cervical lymphadenopathy associated with B symptoms. It is often also found in mediastinal, inguinal, and retroperitoneal lymph nodes. Extranodal RDD presentation is common.
- Hallmark histopathologic features of nodal RDD include dilated sinusoidal spaces filled with large histiocytes with a round to oval hypochromatic nucleus, an inconspicuous to distinct nucleolus, and abundant foamy to clear cytoplasm engulfing a variable number of intact inflammatory cells—namely emperipolesis, a phenomenon recognized in either physiologic or pathologic process. Large histiocytes are positive for monocyte-macrophage markers (ie, S100, CD68, CD163) and negative for LCH markers (ie, CD1a, Langerin [CD207]). Cyclin D1/BCL1 IHC can be helpful to confirm the diagnosis. There are often increased polyclonal plasma cells, and further study is needed for confirmation of IgG4 disorder.[26] Extranodal RDD shows more fibrosis and less frequent emperipolesis.[27]
- A subset of patients with RDD harbor gene mutations involving *NRAS, KRAS, MAP2K1/2,* and rarely *BRAF*.[23,28,29]
- Inherited conditions predisposing to RDD are typically seen in pediatric patients but could be considered in adolescents and young adults:
  - Another heterozygous germline gene mutation involving the *FAS* gene is *TNFRSF6*, which is found in 40% of patients with RDD who had an ALPS type Ia.
  - *SLC29A3* germline gene mutation leading to familial or Faisalabad histiocytosis and H syndrome (histiocytosis-lymphadenopathy plus syndrome).

References on HIST-C 5 of 6

Continued

Note: All recommendations are category 2A unless otherwise indicated.

Version 2.2025, 11/21/25 © 2025 National Comprehensive Cancer Network® (NCCN®), All rights reserved. NCCN Guidelines® and this illustration may not be reproduced in any form without the express written permission of NCCN.

PLEASE NOTE that use of this NCCN Content is governed by the End-User License Agreement, and you MAY NOT distribute this Content or use it with any artificial intelligence model or tool.
Printed by Máximo López Chenlo on 5/4/2026 6:21:12 PM. Copyright © 2026 National Comprehensive Cancer Network, Inc. All Rights Reserved.

SUMMARY OF PATHOLOGIC AND MOLECULAR FEATURES OF HISTIOCYTIC NEOPLASMS[1]

Disease	LCH	ECD	RDD
Pathologic features			
• Xanthomatous histiocytes	No	Yes	No
• Touton giant cells	No	Yes (mainly dermal sites)	No
• Emperipolesis	No	Rare	Abundant
Cytologic features			
• Nuclei	• Oval; retiform, irregular nuclear contours or grooves	• Bland; round-to-oval; small; no grooves	• Large round; hypochromatic
• Nucleoli	• Inconspicuous	• Inconspicuous	• Variable inconspicuous to distinct
• Cytoplasm	• Abundant; eosinophilic	• Classically abundant, amorphous lipid-laden or granular/xanthomatous but often overlap with JXG/AXG*	• Abundant foamy, clear without xanthomatous features; frequent emperipolesis
Background cells	• Increased eosinophils, eosinophilic microabscesses	• Inflammatory cells including few small lymphocytes and plasma cells, rare eosinophils, and dense fibrosis	• Increased mature plasma cells, polyclonal, IgG4; occasional neutrophils

* JXG: juvenile xanthogranuloma; AXG: adult xanthogranuloma.

[1] Adapted with permission from Goyal G, Heaney ML, Collin M, et al. Erdheim-Chester disease: consensus recommendations for evaluation, diagnosis, and treatment in the molecular era. Blood 2020;135:1929-1945.

Continued

Note: All recommendations are category 2A unless otherwise indicated.

Version 2.2025, 11/21/25 © 2025 National Comprehensive Cancer Network® (NCCN®), All rights reserved. NCCN Guidelines® and this illustration may not be reproduced in any form without the express written permission of NCCN.

PLEASE NOTE that use of this NCCN Content is governed by the End-User License Agreement, and you MAY NOT distribute this Content or use it with any artificial intelligence model or tool.
Printed by Máximo López Chenlo on 5/4/2026 6:21:12 PM. Copyright © 2026 National Comprehensive Cancer Network, Inc. All Rights Reserved.

SUMMARY OF PATHOLOGIC AND MOLECULAR FEATURES OF HISTIOCYTIC NEOPLASMS[1]

Disease	LCH	ECD	RDD
Molecular Features			
• *BRAF* V600E (VE1)	55%	50%	3%
• *MAP2K1*	15%	18%	15%
• *RAS* isoforms (*KRAS*, *NRAS*)	2%	8%	30%
• *BRAF* deletions	6%	2%	None
• PI3K isoforms (*PIK3CA, PIK3CD*)	1%	3%	None
• *ARAF*	1%	4%	3%
• Other *BRAF* missense	3%	None	None
• *RAF1*	None	1%	None
• *MAP2K2*	None	1%	None
• *MAP3K1*	Reported	(1 case) (Amplification)	None
• *CSF1R*	1%	1%	1%
• *BRAF* fusions	3%	2%	None
• *ALK* fusions	None	3%	None
• *NTRK1* fusions	None	1%	None
• *RET* fusions	1%	1%	1%
Immunophenotype			
• CD68 (cytoplasmic)	+ (paranuclear cytoplasmic dot)	++	++
• CD163 (surface)	-	++	++
• CD14 (surface)	-	++	++
• CD1a (surface)	++	-	-
• Langerin (CD207) (cytoplasmic)	++	-	-
• Cyclin D1	+	+/-	+/-
• S100 (cytoplasmic/nuclear)	+	+/-	+
• Factor XIIIa (cytoplasmic)	-	+	+/-
• Fascin (cytoplasmic)	-	+	+
• *BRAF* V600E (VE1) (cytoplasmic)[a]	+/-*	+/-*	- (Rare case reports++)
• *ALK* (cytoplasmic)[b]	-	+/-*	-
• *NTRK1* (cytoplasmic)	-	+/-	-
• OCT2	-	-	+

Immunophenotype key: ++, strongly positive; +, weakly positive; +/-, positive or negative; -, negative.
*Moderate to strong positivity should correlate with molecular alteration.

Footnotes
[a] Negative or equivocal IHC for *BRAF* V600E (VE1) does not exclude mutated *BRAF* V600E. Test with NGS panel to cover the common mutations, including *BRAF*, *MAP2K1/2*, *NRAS*, and *KRAS*.
[b] Testing *BRAF, ALK, RET, and NTRK1* fusions is recommended if clinically histiocytosis is suspected and NGS panel testing does not reveal *BRAF* or other MAPK pathway mutations. Testing for somatic mutations using NGS first or in parallel is recommended.

[1] Adapted with permission from Goyal G, Heaney ML, Collin M, et al. Erdheim-Chester disease: consensus recommendations for evaluation, diagnosis, and treatment in the molecular era. Blood 2020;135:1929-1945.

Continued

Note: All recommendations are category 2A unless otherwise indicated.

Version 2.2025, 11/21/25 © 2025 National Comprehensive Cancer Network® (NCCN®), All rights reserved. NCCN Guidelines® and this illustration may not be reproduced in any form without the express written permission of NCCN.

PLEASE NOTE that use of this NCCN Content is governed by the End-User License Agreement, and you MAY NOT distribute this Content or use it with any artificial intelligence model or tool.
Printed by Máximo López Chenlo on 5/4/2026 6:21:12 PM. Copyright © 2026 National Comprehensive Cancer Network, Inc. All Rights Reserved.

REFERENCES

[1] Aramin H, Zaleski M, Prieto VG, Aung PP. Skin and superficial soft tissue neoplasms with multinucleated giant cells: clinical, histologic, phenotypic, and molecular differentiating features. Ann Diagn Pathol 2019;42:18-32.
[2] Ruby KN, Deng AC, Zhang J, et al. Emperipolesis and S100 expression may be seen in cutaneous xanthogranulomas: a multi-institutional observation. J Cutan Pathol 2018 May 24. Online ahead of print.
[3] Chatterjee D, Vishwajeet V, Saikia UN, et al. CyclinD1 is useful to differentiate Langerhans cell histiocytosis from reactive Langerhans cells. Am J Dermatopathol 2019;41:188-192.
[4] Shanmugam V, Craig JW, Hornick JL, et al. Cyclin D1 is expressed in neoplastic cells of Langerhans cell histiocytosis but not reactive Langerhans cell proliferations. Am J Surg Pathol 2017;41:1390-1396.
[5] Baraban E, Sadigh S, Rosenbaum J, et al. Cyclin D1 expression and novel mutational findings in Rosai-Dorfman disease. Br J Haematol 2019;186:837-844.
[6] Chang KTE, Tay AZE, Kuick CH, et al. ALK-positive histiocytosis: an expanded clinicopathologic spectrum and frequent presence of KIF5B-ALK fusion. Mod Pathol 2019;32:598-608.
[7] Murakami N, Sakai T, Arai E, et al. Targetable driver mutations in multicentric reticulohistiocytosis. Haematologica 2020;105:e61-e64.
[8] Ozkaya N, Rosenblum MK, Durham BH, et al. The histopathology of Erdheim-Chester disease: a comprehensive review of a molecularly characterized cohort. Mod Pathol 2018;31:581-597.
[9] Papo M, Diamond EL, Cohen-Aubart F, et al. High prevalence of myeloid neoplasms in adults with non-Langerhans cell histiocytosis. Blood 2017;130:1007-1013.
[10] Galluzzo ML, Braier J, Rosenzweig SD, et al. Bone marrow findings at diagnosis in patients with multisystem Langerhans cell histiocytosis. Pediatr Dev Pathol 2010;13:101-106.
[11] Tzankov A, Kremer M, Leguit R, et al. Histiocytic cell neoplasms involving the bone marrow: summary of the workshop cases submitted to the 18th Meeting of the European Association for Haematopathology (EAHP) organized by the European Bone Marrow Working Group, Basel 2016. Ann Hematol 2018;97:2117-2128.
[12] Ma J, Laird JH, Chau KW, et al. Langehans cell histiocytosis in adults is associated with a high prevalence of hematologic and solid malignancies. Cancer Med 2019;8:58-66.
[13] Goyal G, Shah MV, Hook CC, et al. Adult disseminated Langerhans cell histiocytosis: incidence, racial disparities and long-term outcomes. Br J Haematol 2018;2:579-581.
[14] Papo M, Diamond EL, Cohen-Aubard F, et al. High prevalence of myeloid neoplasms in adults with non-Langerhans cell histiocytosis. Blood 2017;130:1007-1013.
[15] Goyal G, Acosta-Medina AA, Abeykoon JP, et al. Long-term outcomes among adults with Langerhans cell histiocytosis. Blood Adv 2023;7:6568-6578.
[16] Acosta-Medina AA, Abeykoon JP, Go RS, et al. BRAF testing modalities in histiocytic disorders: Comparative analysis and proposed testing algorithm. Am J Clin Pathol 2023;160:483-489.
[17] Diamond EL, Durham BH, Haroche J, et al. Diverse and targetable kinase alterations drive histiocytic neoplasms. Cancer Discov 2016;6:154-165.
[18] Cai J, Huang X, Yin M, et al. A novel fusion gene PLEKHA6-NTRK3 in Langerhans cell histiocytosis. Int J Cancer 2019;144:117-124.
[19] Durham BH, Rodrigo EL, Picarsic J, et al. Activating mutation in CSF1R and additional receptor tyrosine kinases in histiocytic neoplasms. Nat Med 2019;25:1839-1842.
[20] Ballester LY, Cantu MD, Lim KPH, et al. The use of BRAF V600E mutation-specific immunohistochemistry in pediatric Langerhans cell histiocytosis. Hematol Oncol 2018;36:307-315.
[21] Nann D, Schneckenburger P, Steinhilber J, et al. Pediatric Langerhans cell histiocytosis: the impact of mutational profile on clinical progression and late sequelae. Ann Hematol 2019;98:1617-1626.
[22] Hélias-Rodzewicz Z, Donadieu J, Terrones N, et al. Molecular and clinicopathologic characterization of pediatric histiocytoses. Am J Hematol 2023;98:1058-1069.
[23] Janku F, Diamond EL, Goodman AM, et al. Molecular profiling of tumor tissue and plasma cell-free DNA from patients with non-Langerhans cell histiocytosis. Mol Cancer Ther 2019;18:1149-1157.
[24] Emile JF, Abla O, Fraitag S, et al. Revised classification of histiocytoses and neoplasms of the macrophage-dendritic cell lineages. Blood 2016;127:2672-2681.
[25] Picarsic J, Pysher T, Zhou H, et al. BRAF V600E mutation in juvenile xanthogranuloma family neoplasms of the central nervous system (CNS-JXG): a revised diagnostic algorithm to include pediatric Erdheim-Chester disease. Acta Neuropathol Commun 2019;7:168.

Note: All recommendations are category 2A unless otherwise indicated.

Continued

Version 2.2025, 11/21/25 © 2025 National Comprehensive Cancer Network® (NCCN®), All rights reserved. NCCN Guidelines® and this illustration may not be reproduced in any form without the express written permission of NCCN.

PLEASE NOTE that use of this NCCN Content is governed by the End-User License Agreement, and you MAY NOT distribute this Content or use it with any artificial intelligence model or tool.
Printed by Máximo López Chenlo on 5/4/2026 6:21:12 PM. Copyright © 2026 National Comprehensive Cancer Network, Inc. All Rights Reserved.

REFERENCES

[26] Deshpande V, Zen Y, Chan JK, et al. Consensus statement on the pathology of IgG4-related disease. Mod Pathol 2012;25:1181-1192.
[27] Abla O, Jacobsen E, Picarsic J, et al. Consensus recommendations for the diagnosis and clinical management of Rosai-Dorfman-Destombes disease. Blood 2018;131:2877-2890.
[28] Garces S, Medeiros LJ, Patel KP, et al. Mutually exclusive recurrent KRAS and MAP2K1 mutations in Rosai-Dorfman disease. Mod Pathol 2017;30:1367-1377.
[29] Fatobene G, Haroche J, Helias-Rodzwicz Z, et al. BRAF V600E mutation detected in a case of Rosai-Dorfman disease. Haematologica 2018;103:e377-e379.

Note: All recommendations are category 2A unless otherwise indicated.

Version 2.2025, 11/21/25 © 2025 National Comprehensive Cancer Network® (NCCN®), All rights reserved. NCCN Guidelines® and this illustration may not be reproduced in any form without the express written permission of NCCN.

PLEASE NOTE that use of this NCCN Content is governed by the End-User License Agreement, and you MAY NOT distribute this Content or use it with any artificial intelligence model or tool.
Printed by Máximo López Chenlo on 5/4/2026 6:21:12 PM. Copyright © 2026 National Comprehensive Cancer Network, Inc. All Rights Reserved.

PRINCIPLES OF SYSTEMIC THERAPY[a,b]

Adult Langerhans Cell Histiocytosis
- **Regimens may be used in the first- or subsequent-line setting.**

	Preferred	Other Recommended	Useful in Certain Circumstances
Multisystem or single-system lung LCH	***BRAF* V600E-mutated disease** • Vemurafenib[c,1,2] **MAP kinase pathway mutation, or no other detectable/actionable mutation, or testing not available** • Cobimetinib[c,3] **Irrespective of mutation** • Cytarabine[4,5] • Cladribine[6,7]	***BRAF* V600E-mutated disease** • Dabrafenib[c,2,12] **MAP kinase pathway mutation, or no other detectable/actionable mutation, or testing not available** • Trametinib[c,12-16] • Binimetinib [c,d,12-16] • Selumetinib[c,d,12-16] **Irrespective of mutation** • Methotrexate (oral) [9,10] • Hydroxyurea[11] • Clofarabine[17] • Vinblastine/prednisone[4] • Methotrexate + cytarabine[18]	• Crizotinib for *ALK* fusion[21] • Pexidartinib for *CSF1R* mutation[21] • Larotrectinib for *NTRK* gene fusion[22,23] • Entrectinib for *NTRK* gene fusion[22,24] • Repotrectinib for *NTRK* gene fusion[25] • Sirolimus or everolimus for *PIK3CA* mutation[26,27] • Selpercatinib for *RET* fusion[21] **Relapsed/Refractory** • Allogeneic hematopoietic cell transplant (for highly select patients)[28,29]
Bone disease only	• Bisphosphonates ▸ Zoledronic acid[8] ▸ Pamidronate[8]	• None	Multifocal single-system bone disease not responsive to bisphosphonate • See preferred, other recommended, and useful in certain circumstances options above for multisystem disease
• Single-system multifocal skin disease (including mucosa)	• Methotrexate (oral)[9,10] • Hydroxyurea[11]	• Lenalidomide[19] • Thalidomide[20]	• None

[a] Recommend starting targeted agents at lower dose. See Principles of Targeted Therapy (HIST-F).
[b] Some therapies have not been studied in histiocytic disease; thus, some data are being extrapolated from other disease sites.
[c] See Principles of Targeted Therapy (HIST-F).
[d] If cobimetinib or trametinib are not tolerated.

Note: All recommendations are category 2A unless otherwise indicated.

References on HIST-D 6 of 8
Continued

Version 2.2025, 11/21/25 © 2025 National Comprehensive Cancer Network® (NCCN®), All rights reserved. NCCN Guidelines® and this illustration may not be reproduced in any form without the express written permission of NCCN.

PLEASE NOTE that use of this NCCN Content is governed by the End-User License Agreement, and you MAY NOT distribute this Content or use it with any artificial intelligence model or tool.
Printed by Máximo López Chenlo on 5/4/2026 6:21:12 PM. Copyright © 2026 National Comprehensive Cancer Network, Inc. All Rights Reserved.

PRINCIPLES OF SYSTEMIC THERAPY[a,b]

Adult Langerhans Cell Histiocytosis
• Regimens may be used in the first- or subsequent-line setting.

	Preferred	Other Recommended	Useful in Certain Circumstances
CNS lesions	***BRAF* V600E-mutated disease** • Vemurafenib[c,1,2] **MAP kinase pathway mutation, or no other detectable/actionable mutation, or testing not available** • Cobimetinib[c,3] **Irrespective of mutation** • Cytarabine[e,4] • Cladribine[6,7]	***BRAF* V600E-mutated disease** • Dabrafenib[c,2,12] **MAP kinase pathway mutation, or no other detectable/actionable mutation, or testing not available** • Trametinib[c,12-16] • Binimetinib[c,d,12-16] • Selumetinib[c,d,12-16] **Irrespective of mutation** • High-dose methotrexate[30] • Methotrexate + cytarabine[18]	• Crizotinib for *ALK* fusion[21] • Pexidartinib for *CSF1R* mutation[21] • Larotrectinib for *NTRK* gene fusion[22,23] • Entrectinib for *NTRK* gene fusion[22,24] • Repotrectinib for *NTRK* gene fusion[25] • Sirolimus or everolimus for *PIK3CA* mutation[26,27] • Selpercatinib for *RET* fusion[21]

[a] Recommend starting targeted agents at lower dose. See Principles of Targeted Therapy (HIST-F).
[b] Some therapies have not been studied in histiocytic disease; thus, some data are being extrapolated from other disease sites.
[c] See Principles of Targeted Therapy (HIST-F).
[d] If cobimetinib or trametinib are not tolerated.
[e] Higher dose (150 mg/m^2) is indicated for CNS lesions.

Note: All recommendations are category 2A unless otherwise indicated.

References on HIST-D 6 of 8

Continued

Version 2.2025, 11/21/25 © 2025 National Comprehensive Cancer Network® (NCCN®), All rights reserved. NCCN Guidelines® and this illustration may not be reproduced in any form without the express written permission of NCCN.

PLEASE NOTE that use of this NCCN Content is governed by the End-User License Agreement, and you MAY NOT distribute this Content or use it with any artificial intelligence model or tool.
Printed by Máximo López Chenlo on 5/4/2026 6:21:12 PM. Copyright © 2026 National Comprehensive Cancer Network, Inc. All Rights Reserved.

PRINCIPLES OF SYSTEMIC THERAPY[a,b]

Pediatric Langerhans Cell Histiocytosis
- **Regimens may be used in the first- or subsequent-line setting**

	Preferred	Other Recommended	Useful in Certain Circumstances
Multisystem or single-system lung LCH	**Irrespective of mutation** • Vinblastine/prednisone ± 6-mercaptopurine[31] • Cladribine[32] • Cytarabine[33] • Clofarabine[34,35]	***BRAF* V600E mutated disease** • Dabrafenib • Vemurafenib **MAP kinase pathway mutation, or no other detectable/actionable mutation, or testing not available** • Binimetinib • Cobimetinib • Selumetinib • Trametinib	• Other targeted agents may be considered for disease with other uncommon targetable mutations (see adult Langerhans cell histiocytosis regimens [HIST-D 1]) but may not be approved by the FDA
Bone disease only	• Bisphosphonate (zoledronic acid)[8] • Indomethacin[36] • Vinblastine/prednisone ± 6-mercaptopurine[31]		
CNS lesions	• LCH mass lesions[f] ▸ Vinblastine/prednisone[31] ▸ Cytarabine • LCH-associated abnormal CNS imaging/ Neurodegeneration (LACI/ND): ▸ Cytarabine ± IVIG[37] ▸ MAPKi (vemurafenib, dabrafenib [BRAF inhibitor]; trametinib, selumetinib [MAPK inhibitor]) with CNS penetration		

[a] Recommend starting targeted agents at lower dose. See Principles of Targeted Therapy (HIST-F).
[b] Some therapies have not been studied in histiocytic disease, thus, some data are being extrapolated from other disease sites.
[f] Hypothalamic-pituitary involvement; enlargement and enhancement of the pineal gland; thickening and enhancement of the choroid plexus; intraparenchymal masses

Note: All recommendations are category 2A unless otherwise indicated.

References on HIST-D 6 of 8

Continued

Version 2.2025, 11/21/25 © 2025 National Comprehensive Cancer Network® (NCCN®), All rights reserved. NCCN Guidelines® and this illustration may not be reproduced in any form without the express written permission of NCCN.

PLEASE NOTE that use of this NCCN Content is governed by the End-User License Agreement, and you MAY NOT distribute this Content or use it with any artificial intelligence model or tool.
Printed by Máximo López Chenlo on 5/4/2026 6:21:12 PM. Copyright © 2026 National Comprehensive Cancer Network, Inc. All Rights Reserved.

PRINCIPLES OF SYSTEMIC THERAPY[a,b]

Erdheim-Chester Disease
- **Regimens may be used in the first- or subsequent-line setting.**

Preferred	Other Recommended	Useful in Certain Circumstances
***BRAF* V600E-mutated disease** • Vemurafenib[c,1,38] **MAP kinase pathway mutation, or no other detectable/actionable mutation, or testing not available** • Cobimetinib[c,39]	***BRAF* V600E-mutated disease** • Dabrafenib[c,39,40] **MAP kinase pathway mutation, or no other detectable/actionable mutation, or testing not available** • Trametinib[c,14,41] **Irrespective of mutation** • Cladribine[42] • Pegylated interferon alpha-2a and alpha-2b[g,43] • Sirolimus + prednisone[44] • Methotrexate (oral)[45] • Anakinra[c,46,47]	• Crizotinib for *ALK* fusion[21] • Alectinib for *ALK* fusion[48] • Brigatinib for *ALK* fusion[48] • Ceritinib for *ALK* fusion[48] • Lorlatinib for *ALK* fusion[48] • Pexidartinib for *CSF1R* mutation[21,49] • Larotrectinib for *NTRK* gene fusion[22,23] • Entrectinib for *NTRK* gene fusion[22,24] • Repotrectinib for *NTRK* gene fusion[25] • Sirolimus or everolimus for *PIK3CA* mutation[26,27] • Selpercatinib for *RET* fusion[21]

[a] Recommend starting targeted agents at lower dose. See Principles of Targeted Therapy (HIST-F).
[b] Some therapies have not been studied in histiocytic disease; thus, some data are being extrapolated from other disease sites.
[c] See Principles of Targeted Therapy (HIST-F).
[g] Peginterferon alfa-2a is the only peginterferon alfa available for clinical use in the United States and it may be substituted for peginterferon alfa-2b (Schiller M, et al. J Eur Acad Dermatol Venerol 2017;31:1841-1847; Patsatsi A, et al. J Eur Acad Dermatol Venereol 2022;36:e291-e293; Osman S, et al. Dermatologic Therapy 2023;2023:7171937).

Note: All recommendations are category 2A unless otherwise indicated.

References on HIST-D 6 of 8
Continued

Version 2.2025, 11/21/25 © 2025 National Comprehensive Cancer Network® (NCCN®), All rights reserved. NCCN Guidelines® and this illustration may not be reproduced in any form without the express written permission of NCCN.

PLEASE NOTE that use of this NCCN Content is governed by the End-User License Agreement, and you MAY NOT distribute this Content or use it with any artificial intelligence model or tool.
Printed by Máximo López Chenlo on 5/4/2026 6:21:12 PM. Copyright © 2026 National Comprehensive Cancer Network, Inc. All Rights Reserved.

PRINCIPLES OF SYSTEMIC THERAPY[a,b]

Rosai-Dorfman Disease
- **Regimens may be used in the first- or subsequent-line setting.**

Preferred	Other Recommended	Useful in Certain Circumstances
MAP kinase pathway mutation, or no other detectable/actionable mutation, or testing not available • Cobimetinib[c,50,51] **Irrespective of mutation** • Cladribine[52] • Cytarabine[53] • Methotrexate (oral)[54,55] • Prednisone or other corticosteroid[52]	**MAP kinase pathway mutation, or no other detectable/actionable mutation, or testing not available** • Trametinib[c,14] **Irrespective of mutation** • Vinblastine + prednisone[56] • Methotrexate (IV or SC)[57,58] • Lenalidomide[59-61]	• Crizotinib for *ALK* fusion[21] • Pexidartinib for *CSF1R* mutation[21] • Larotrectinib for *NTRK* gene fusion[22,23] • Entrectinib for *NTRK* gene fusion[22,24] • Repotrectinib for *NTRK* gene fusion[25] • Everolimus for *PIK3CA* mutation[26,27] • Selpercatinib for *RET* fusion[21] • Sirolimus (for those associated with ALPS and/or *PIK3CA* mutation)[26,27,62] **Irrespective of mutation** • Rituximab[h] (for IgG4-related, nodal and immune-cytopenia diseases)[63] • Thalidomide (for cutaneous involvement only)[64]

[a] Recommend starting targeted agents at lower dose. See Principles of Targeted Therapy (HIST-F).
[b] Some therapies have not been studied in histiocytic disease; thus, some data are being extrapolated from other disease sites.
[c] See Principles of Targeted Therapy (HIST-F).
[h] An FDA-approved biosimilar is an appropriate substitute for rituximab.

Note: All recommendations are category 2A unless otherwise indicated.

References on HIST-D 6 of 8
Continued

Version 2.2025, 11/21/25 © 2025 National Comprehensive Cancer Network® (NCCN®), All rights reserved. NCCN Guidelines® and this illustration may not be reproduced in any form without the express written permission of NCCN.

PLEASE NOTE that use of this NCCN Content is governed by the End-User License Agreement, and you MAY NOT distribute this Content or use it with any artificial intelligence model or tool.
Printed by Máximo López Chenlo on 5/4/2026 6:21:12 PM. Copyright © 2026 National Comprehensive Cancer Network, Inc. All Rights Reserved.

REFERENCES

[1] Diamond EL, Subbiah V, Lockhart AC, et al. Vemurafenib for BRAF V600-mutant Erdheim-Chester disease and Langerhans cell histiocytosis: analysis of data from the histology-independent, phase 2, open-label VE-BASKET Study. JAMA Oncol 2018;4:384-388.
[2] Hazim AZ, Ruan GJ, Ravindran A, et al. Efficacy of BRAF-inhibitor therapy in BRAF(V600E)-mutated adult Langerhans cell histiocytosis. Oncologist 2020;25:1001-1004.
[3] Diamond EL, Durham BH, Ulaner GA, et al. Efficacy of MEK inhibition in patients with histiocytic neoplasms. Nature 2019;567:521-524.
[4] Cantu MA, Lupo PJ, Bilgi M, et al. Optimal therapy for adults with Langerhans cell histiocytosis bone lesions. PLoS One 2012;7:e43257.
[5] Miao HL, Zhao AL, Duan MH, et al. Clinical presentation and prognostic analysis of adult patients with Langerhans cell histiocytosis with pulmonary involvement. BMC Cancer 2020;20:911.
[6] Goyal G, Abeykoon JP, Hu M, et al. Single-agent cladribine as an effective front-line therapy for adults with Langerhans cell histiocytosis. Am J Hematol 2021;96:E146-E150.
[7] Saven A, Burian C. Cladribine activity in adult Langerhans-cell histiocytosis. Blood 1999;93:4125-4130.
[8] Chellapandian D, Makras P, Kaltsas G, et al. Bisphosphonates in Langerhans cell histiocytosis: an international retrospective case series. Mediterr J Hematol Infect Dis 2016;8:e2016033.
[9] Steen AE, Steen KH, Bauer R, Bieber T. Successful treatment of cutaneous Langerhans cell histiocytosis with low-dose methotrexate. Br J Dermatol 2001;145:137-140.
[10] Womer RB, Anunciato KR, Chehrenama M. Oral methotrexate and alternate-day prednisone for low-risk Langerhans cell histiocytosis. Med Pediatr Oncol 1995;25:70-73.
[11] Zinn DJ, Grimes AB, Lin H, et al. Hydroxyurea: A new old therapy for Langerhans cell histiocytosis. Blood 2016;128:2462-2465.
[12] Awada G, Seremet T, Fostier K, et al. Long-term disease control of Langerhans cell histiocytosis using combined BRAF and MEK inhibition. Blood Adv 2018;2:2156-2158.
[13] Lorillon G, Jouenne F, Baroudjian B, et al. Response to trametinib of a pulmonary Langerhans cell histiocytosis harboring a MAP2K1 deletion. Am J Respir Crit Care Med 2018;198:675-678.
[14] Aaroe A, Kurzrock R, Goyal G, et al. Successful treatment of non-langerhans cell histiocytosis with the MEK inhibitor Trametinib: a multicenter analysis. Blood Adv 2023;7:3984-3992.
[15] Messinger YH, Bostrom BC, Olson DR, et al. Langerhans cell histiocytosis with BRAF p.N486_P490del or MAP2K1 p.K57_G61del treated by the MEK inhibitor trametinib. Pediatr Blood Cancer 2020;67:e28712.
[16] Papapanagiotou M, Griewank KG, Hillen U, et al. Trametinib-induced remission of an MEK1-mutated Langerhans cell histiocytosis. JCO Precis Oncol 2017:1-5.
[17] Simko SJ, Tran HD, Jones J, et al. Clofarabine salvage therapy in refractory multifocal histiocytic disorders, including Langerhans cell histiocytosis, juvenile xanthogranuloma and Rosai-Dorfman disease. Pediatr Blood Cancer 2014;61:479-487.
[18] Cao XX, Li J, Zhao AL, et al. Methotrexate and cytarabine for adult patients with newly diagnosed Langerhans cell histiocytosis: a single arm, single center, prospective phase 2 study. Am J Hematol 2020;95:E235-E238.
[19] Szturz P, Adam Z, Rehak Z, et al. Lenalidomide proved effective in multisystem Langerhans cell histiocytosis. Acta Oncol 2012;51:412-415.
[20] McClain KL, Kozinetz CA. A phase II trial using thalidomide for Langerhans cell histiocytosis. Pediatr Blood Cancer 2007;48:44-49.
[21] Durham BH, Lopez Rodrigo E, Picarsic J, et al. Activating mutations in CSF1R and additional receptor tyrosine kinases in histiocytic neoplasms. Nat Med 2019;25:1839-1842.
[22] Taylor J, Pavlick D, Yoshimi A, et al. Oncogenic TRK fusions are amenable to inhibition in hematologic malignancies. J Clin Invest 2018;128:3819-3825.
[23] Drilon A, Laetsch TW, Kummar S, et al. Efficacy of larotrectinib in TRK fusion-positive cancers in adults and children. N Engl J Med 2018;378:731-739.
[24] Doebele RC, Drilon A, Paz-Ares L, et al. Entrectinib in patients with advanced or metastatic NTRK fusion-positive solid tumours: integrated analysis of three phase 1-2 trials. Lancet Oncol 2020;21:271-282.
[25] Solomon B, Drilon A, Lin JJ, et al. Repotrectinib in patients with NTRK fusion-positive advanced solid tumors, including non-small cell lung cancer: update from the phase 1/2 TRIDENT-1 trial. Poster presented at the European Society for Medical Oncology Congress, Madrid, Spain, October 20-24, 2023.
[26] van Bommel EFH, van der Zijden MA, Smak Gregoor PJH, et al. Sirolimus monotherapy for Erdheim-Chester disease. Acta Oncol 2019;58:901-905.
[27] Emile JF, Diamond EL, Helias-Rodzewicz Z, et al. Recurrent RAS and PIK3CA mutations in Erdheim-Chester disease. Blood 2014;124:3016-3019.
[28] Ingram W, Desai SR, Gibbs JSR, et al. Reduced-intensity conditioned allogeneic haematopoietic transplantation in an adult with Langerhans' cell histiocytosis and thrombocytopenia with absent radii. Bone Marrow Transplant 2006;37:713-715.

Continued

Note: All recommendations are category 2A unless otherwise indicated.

Version 2.2025, 11/21/25 © 2025 National Comprehensive Cancer Network® (NCCN®), All rights reserved. NCCN Guidelines® and this illustration may not be reproduced in any form without the express written permission of NCCN.

PLEASE NOTE that use of this NCCN Content is governed by the End-User License Agreement, and you MAY NOT distribute this Content or use it with any artificial intelligence model or tool.
Printed by Máximo López Chenlo on 5/4/2026 6:21:12 PM. Copyright © 2026 National Comprehensive Cancer Network, Inc. All Rights Reserved.

REFERENCES

[29] Xicoy B, Ribera JM, Batlle M, et al. [Sustained remission in an adult patient with Langerhans cell histiocytosis following T-cell depleted allogenic cell transplantation]. Med Clin (Barc) 2006;127:716.
[30] Ho P, Smith C. High-dose methotrexate for the treatment of relapsed central nervous system Erdheim-Chester disease. Case Rep Hematol 2014;2014:269359.
[31] Gadner H, Minkov M, Grois N, et al. Therapy prolongation improves outcome in multisystem Langerhans cell histiocytosis. Blood 2013;121:5006-14.
[32] Donadieu J, Bernard F, van Noesel M, et al. Cladribine and cytarabine in refractory multisystem Langerhans cell histiocytosis: results of an international phase 2 study. Blood 2015;126:1415-23.
[33] Eckstein OS, Bernhardt MB, Hood CG, et al. Treatment of Langerhans cell histiocytosis with subcutaneous cytarabine. Pediatr Hematol Oncol 2023;40:497-505.
[34] Parekh D, Lin H, McClain KL, et al. Retrospective analysis of clofarabine salvage therapy in refractory ,multifocal Langerhans cell histiocytosis (LCH). Blood 2023 (Supplement 1):4574.
[35] Parekh D, Lin H, Batajoo, et al. Clofarabine monotherapy in aggressive, relapsed and refractory Langerhans cell histiocytosis. Br J Haematol 2024;204:1888-1893.
[36] Benedittis DD, Mohamed S, Rizzo L, et al. Indomethacin is an effective treatment in adults and children with bone Langerhans cell histiocytosis (LCH). Br J Haematol 2020;191:e109-e113.
[37] Allen CE, Flores R, Rauch R, et al. Neurodegenerative central nervous system Langerhans cell histiocytosis and coincident hydrocephalus treated with vincristine/cytosine arabinoside. Pediatr Blood Cancer 2010;54:416-23.
[38] Ruan GJ, Hazim A, Abeykoon JP, et al. Low-dose vemurafenib monotherapy in BRAF(V600E) -mutated Erdheim-Chester disease. Leuk Lymphoma 2020;61:2733-2737.
[39] Cohen Aubart F, Emile JF, Carrat F, et al. Targeted therapies in 54 patients with Erdheim-Chester disease, including follow-up after interruption (the LOVE study). Blood 2017;130:1377-1380.
[40] Bhatia A, Ulaner G, Rampal R, et al. Single-agent dabrafenib for BRAF(V600E)-mutated histiocytosis. Haematologica 2018;103:e177-e180.
[41] Nordmann TM, Juengling FD, Recher M, et al. Trametinib after disease reactivation under dabrafenib in Erdheim-Chester disease with both BRAF and KRAS mutations. Blood 2017;129:879-882.
[42] Goyal G, Shah MV, Call TG, et al. Clinical and radiologic responses to cladribine for the treatment of Erdheim-Chester disease. JAMA Oncol 2017;3:1253-1256.
[43] Cohen Aubart F, Idbaih A, Galanaud D, et al. Central nervous system involvement in Erdheim-Chester disease: an observational cohort study. Neurology 2020;95:e2746-e2754.
[44] Gianfreda D, Nicastro M, Galetti M, et al. Sirolimus plus prednisone for Erdheim-Chester disease: an open-label trial. Blood 2015;126:1163-1171.
[45] Goyal G, Shah MV, Call TG, et al. Clinical and radiological responses to oral methotrexate alone or in combination with other agents in Erdheim-Chester disease. Blood Cancer J 2017;7:647.
[46] Cohen-Aubart F, Maksud P, Saadoun D, et al. Variability in the efficacy of the IL1 receptor antagonist anakinra for treating Erdheim-Chester disease. Blood 2016;127:1509-1512.
[47] Goyal G, Shah MV, Call TG, et al. Efficacy of biological agents in the treatment of Erdheim-Chester disease. Br J Haematol 2018;183:520-524.
[48] Kemps PG, Picarsic J, Durham BH, et al. ALK-positive histiocytosis: a new clinicopathologic spectrum highlighting neurologic involvement and responses to ALK inhibition. Blood 2022;139:256-280.
[49] Abeykoon JP, Lasho TL, Dasari S, et al. Sustained, complete response to pexidartinib in a patient with CSF1R-mutated Erdheim-Chester disease. Am J Hematol 2022;97:293-302.
[50] Moyon Q, Boussouar S, Maksud P, et al. Lung involvement in Destombes-Rosai-Dorfman disease: clinical and radiological features and response to the MEK inhibitor cobimetinib. Chest 2020;157:323-333.
[51] Jacobsen E, Shanmugam V, Jagannathan J. Rosai-Dorfman disease with activating KRAS mutation - Response to cobimetinib. N Engl J Med 2017;377:2398-2399.
[52] Goyal G, Ravindran A, Young JR, et al. Clinicopathological features, treatment approaches, and outcomes in Rosai-Dorfman disease. Haematologica 2020;105:348-357.
[53] Wang W, Sun J, Zhang W, Zhou D. Successful treatment of intracranial Rosai-Dorfman disease with cytarabine and dexamethasone: case report and review of literature. Ann Hematol 2020;99:1157-1159.
[54] Nasseri E, Belisle A, Funaro D. Rosai-Dorfman disease treated with methotrexate and low-dose prednisone: case report and review of the literature. J Cutan Med Surg 2012;16:281-285.
[55] Nadal M, Kervarrec T, Machet MC, et al. Cutaneous Rosai-Dorfman disease located on the breast: rapid effectiveness of methotrexate after failure of topical corticosteroids, acitretin and thalidomide. Acta Derm Venereol 2015;95:758-759.

Continued

Note: All recommendations are category 2A unless otherwise indicated.

Version 2.2025, 11/21/25 © 2025 National Comprehensive Cancer Network® (NCCN®), All rights reserved. NCCN Guidelines® and this illustration may not be reproduced in any form without the express written permission of NCCN.

PLEASE NOTE that use of this NCCN Content is governed by the End-User License Agreement, and you MAY NOT distribute this Content or use it with any artificial intelligence model or tool.
Printed by Máximo López Chenlo on 5/4/2026 6:21:12 PM. Copyright © 2026 National Comprehensive Cancer Network, Inc. All Rights Reserved.

REFERENCES

[56] Cohen-Barak E, Rozenman D, Schafer J, et al. An unusual co-occurrence of Langerhans cell histiocytosis and Rosai-Dorfman disease: report of a case and review of the literature. Int J Dermatol 2014;53:558-563.
[57] Inoue S, Onwuzurike N. Vinorelbine and methotrexate for the treatment of Rosai-Dorfman disease. Pediatr Blood Cancer 2005;45:84-85; author reply 86.
[58] Gawdzik A, Ziarkiewicz-Wroblewska B, Chlebicka I, et al. Cutaneous Rosai-Dorfman disease: A treatment challenge. Dermatol Ther (Heidelb) 2021;11:1443-1448.
[59] Rubinstein M, Assal A, Scherba M, et al. Lenalidomide in the treatment of Rosai Dorfman disease--a first in use report. Am J Hematol 2016;91:E1.
[60] Al-Ghawas MS, Ng T, Chen LYC. Confirmed efficacy of lenalidomide and dexamethasone in unresectable cutaneous facial Rosai-Dorfman-Destombes disease. Mayo Clin Proc Innov Qual Outcomes 2019;3:94-96.
[61] Liu T, Cao X. Successful treatment of multisystemic Rosai-Dorfman disease with lenalidomide and dexamethasone: a case report. Ann Hematol 2022;101:1351-1353.
[62] Golwala ZM, Taur P, Pandrowala A, et al. Sirolimus-a targeted therapy for Rosai-Dorfman disease. Pediatr Blood Cancer 2019;66:e27994.
[63] Rituximab in the treatment of Rosai-Dorfman syndrome with IgG4 disease. J Am Acad Dermatol 2019;81:AB269.
[64] Chen E, Pavlidakey P, Sami N. Rosai-Dorfman disease successfully treated with thalidomide. JAAD Case Rep 2016;2:369-372.

Note: All recommendations are category 2A unless otherwise indicated.

Version 2.2025, 11/21/25 © 2025 National Comprehensive Cancer Network® (NCCN®), All rights reserved. NCCN Guidelines® and this illustration may not be reproduced in any form without the express written permission of NCCN.

PLEASE NOTE that use of this NCCN Content is governed by the End-User License Agreement, and you MAY NOT distribute this Content or use it with any artificial intelligence model or tool.
Printed by Máximo López Chenlo on 5/4/2026 6:21:12 PM. Copyright © 2026 National Comprehensive Cancer Network, Inc. All Rights Reserved.

PRINCIPLES OF SUPPORTIVE CARE[1-4]

Chronic Pain, Fatigue, Depression, Anxiety, and Poor Quality of Life

- **Patients with histiocytic disorders (especially ECD and LCH) often struggle with chronic generalized pain and fatigue that is out of proportion to the disease involvement.**
- **Many of these patients fit the criteria for myalgic encephalomyelitis/chronic fatigue syndrome.**
- **There is a high prevalence of depression and anxiety that compounds these symptoms further.**
- **In some instances, there is residual pain at the site of a tumor bed despite complete resection, especially in the case of bone lesions from LCH.**
- **Chronic pain may not respond well to available analgesic drugs.**
- **These symptoms can worsen the health-related quality of life of these patients significantly.**
- **It is important for clinicians to acknowledge these symptoms fully and refer the patients to appropriate specialties (eg, palliative medicine, psychiatry, psychology).**
- **In cases with severe fatigue, oral stimulants like methylphenidate can be used and appear to be safe for long-term use.**
- **Treatment of depression and anxiety with pharmacotherapy or psychotherapy may help with improvement of these symptoms.**
- **Continue follow-up with pulmonary/neurology/endocrinology specialist during surveillance.**
- **See NCCN Guidelines for Supportive Care:**
  - **Adult Cancer Pain**
  - **Cancer-Related Fatigue**
  - **Distress Management**
  - **Survivorship**

[1] Goyal G, Heaney ML, Collin M, et al. Erdheim-Chester disease: Consensus recommendations for evaluation, diagnosis, and treatment in the molecular era. Blood 2020;135:1929-1945.
[2] Goyal G, Tazi A, Go RS, et al. International expert consensus recommendations for the diagnosis and treatment of Langerhans cell histiocytosis in adults. Blood 2022;139:2601-2621.
[3] Diamond EL, Reiner AS, Buthorn JJ, et al. A scale for patient-reported symptom assessment for patients with Erdheim-Chester disease. Blood Adv 2019;3:934-938.
[4] O'Brein K, Dave R, Shekhar S, et al. Survivorship issues in adult patients with histiocytic neoplasms. J Natl Compr Canc Netw 2021;19:1312-1318.

Note: All recommendations are category 2A unless otherwise indicated.

Version 2.2025, 11/21/25 © 2025 National Comprehensive Cancer Network® (NCCN®), All rights reserved. NCCN Guidelines® and this illustration may not be reproduced in any form without the express written permission of NCCN.

PLEASE NOTE that use of this NCCN Content is governed by the End-User License Agreement, and you MAY NOT distribute this Content or use it with any artificial intelligence model or tool.
Printed by Máximo López Chenlo on 5/4/2026 6:21:12 PM. Copyright © 2026 National Comprehensive Cancer Network, Inc. All Rights Reserved.

PRINCIPLES OF TARGETED THERAPY[a]

Toxicities of BRAF and MEK Inhibitors

- **Most patients are unable to tolerate full doses of BRAF and MEK inhibitors that are approved for melanoma. For patients without CNS involvement, it may be reasonable to start at half the approved dose and modify based on toxicities.**
- **Some patients may be able to tolerate chronic low-dose administration of BRAF and MEK inhibitors, especially after attainment of best response. Dose reductions and treatment breaks are highly individualized with close monitoring for relapse.**
- **ECG monitoring is recommended for patients on BRAF inhibitors as clinically indicated.**
- **Cardiomyopathy may occur with MEK inhibitors. Monitoring is recommended as clinically indicated.**
- **Hypersensitivity reaction may occur with administration. Monitor for and treat hypersensitivity reactions.**
- **Electrolytes (eg, magnesium, potassium) should be monitored prior to and 15 days after initiation of therapy, then monthly during the first 3 months and every 3 months thereafter or as clinically indicated.**
- **Liver function should be monitored prior to initiation of therapy, then monthly or as clinically indicated for potential dose modification or discontinuation.**
- **Renal function should be monitored prior to initiation of therapy and as clinically indicated for potential dose modification or discontinuation.**
- **Serious hemorrhagic events may occur with therapy. Evaluate risk of bleeding prior to initiation of therapy, then monitor for signs and symptoms of bleeding as clinically indicated.**
- **This agent may be associated with hemolytic anemia in patients with glucose-6-phosphate dehydrogenase (G6PD) deficiency. Patients should be monitored for signs and symptoms of hemolytic anemia, and screening for G6PD status may be warranted.**
- **Pyrexia (defined as a temperature of ≥38.3 °C) is a common (~55%) side effect of combining BRAF and MEK inhibitors and occurs less frequently with BRAF inhibitor monotherapy (~20%).[b] The pyrexia is episodic, with a median duration of 9 days, and onset is often 2–4 weeks following the start of therapy. Pyrexia may be associated with chills, night sweats, rash, dehydration, electrolyte abnormalities, and hypotension. Stopping or holding BRAF/MEK inhibitor combination at the onset of pyrexia will often interrupt the episode, and treatment can be resumed with full-dose BRAF/MEK inhibitors upon cessation of pyrexia and pyrexia-related symptoms. Upon re-exposure to BRAF/MEK inhibitors, repeat pyrexia events can occur, but grade >3 events are uncommon (21%). In occasional instances of prolonged or severe pyrexia not responsive to discontinuation of BRAF/MEK inhibitors, low-dose corticosteroids (prednisone 10 mg/day) can be used. Patients with pyrexia should be advised to use antipyretics as needed and increase fluid intake.**

[a] Refer to full prescribing information for individual agents regarding specific and additional information (https://www.accessdata.fda.gov/scripts/cder/daf).
[b] The frequency of pyrexia and other adverse events varies between specific BRAF/MEK inhibitor combinations.

Note: All recommendations are category 2A unless otherwise indicated.

Version 2.2025, 11/21/25 © 2025 National Comprehensive Cancer Network® (NCCN®), All rights reserved. NCCN Guidelines® and this illustration may not be reproduced in any form without the express written permission of NCCN.

PLEASE NOTE that use of this NCCN Content is governed by the End-User License Agreement, and you MAY NOT distribute this Content or use it with any artificial intelligence model or tool.
Printed by Máximo López Chenlo on 5/4/2026 6:21:12 PM. Copyright © 2026 National Comprehensive Cancer Network, Inc. All Rights Reserved.

PRINCIPLES OF TARGETED THERAPY

Toxicities of BRAF and MEK Inhibitors (continued)

- **Regular dermatologic evaluation and referral to a dermatologist or provider experienced in the diagnosis and management of cutaneous manifestations of targeted therapy is recommended. BRAF inhibitors are associated with cutaneous squamous cell carcinoma, extreme photosensitivity, and other dermatologic toxicities, which occur much less often with concurrent MEK inhibitors. Severe and life-threatening[1] skin toxicity (eg, drug-induced hypersensitivity syndrome) can occur with the use of BRAF inhibitors following immune checkpoint blockade, and requires prompt dermatologic consultation for accurate diagnosis and treatment.[2] Cutaneous toxicities of MEK inhibitors most commonly manifest as acneiform rash. Topical benzoyl peroxide with or without oral doxycycline/minocycline may be used at the onset of rash (see Management of Toxicities Associated with Targeted and Immune Therapies (ME-K) in the NCCN Guidelines for Melanoma: Cutaneous).**
- **Serious retinopathy may occur with MEK inhibitors. Monitoring by retinal exam with optical coherence tomography (OCT) is recommended.**

Considerations for Targeted Therapies

- **Patients may not be able to tolerate the full doses of tyrosine kinase inhibitors.**
- **It is generally reasonable to start with one or two dose reductions, and then adjust the dose based on response. See HIST-F 3 of 3.**
- **Consider drug-drug interactions that may occur with concurrent use of specific CYP inhibitors or inducers, along with other interacting classes, by avoiding the interacting drug or adjusting the dose of the targeted agent, as clinically indicated.**

References

[1] Maloney NJ, Rana J, Yang JJ, et al. Clinical features of drug-induced hypersensitivity syndrome to BRAF inhibitors with and without previous immune checkpoint inhibition: A review. Support Care Cancer 2022;30:2839-2851.
[2] Lamiaux M, Scalbert C, Lepesant P, et al. Severe skin toxicity with organ damage under the combination of targeted therapy following immunotherapy in metastatic melanoma. Melanoma Res 2018;28:451-457.

Note: All recommendations are category 2A unless otherwise indicated.

Version 2.2025, 11/21/25 © 2025 National Comprehensive Cancer Network® (NCCN®), All rights reserved. NCCN Guidelines® and this illustration may not be reproduced in any form without the express written permission of NCCN.

PLEASE NOTE that use of this NCCN Content is governed by the End-User License Agreement, and you MAY NOT distribute this Content or use it with any artificial intelligence model or tool.
Printed by Máximo López Chenlo on 5/4/2026 6:21:12 PM. Copyright © 2026 National Comprehensive Cancer Network, Inc. All Rights Reserved.

PRINCIPLES OF TARGETED THERAPY

Recommended Starting Doses for Select Targeted Agents

Drug	Starting Dose (Adjust/Increase Based on Response)[c]
Dabrafenib	50 mg PO twice daily
Cobimetinib	20–40 mg PO daily on days 1–21 of each 28-day cycle
Trametinib	0.5-1 mg PO daily
Vemurafenib	480 mg PO twice daily

[c] Other MEK and BRAF inhibitors not listed should be started at similarly reduced doses.

Note: All recommendations are category 2A unless otherwise indicated.

Version 2.2025, 11/21/25 © 2025 National Comprehensive Cancer Network® (NCCN®), All rights reserved. NCCN Guidelines® and this illustration may not be reproduced in any form without the express written permission of NCCN.

PLEASE NOTE that use of this NCCN Content is governed by the End-User License Agreement, and you MAY NOT distribute this Content or use it with any artificial intelligence model or tool.
Printed by Máximo López Chenlo on 5/4/2026 6:21:12 PM. Copyright © 2026 National Comprehensive Cancer Network, Inc. All Rights Reserved.

PRINCIPLES OF RADIATION THERAPY

Pediatric and Adult Langerhans Cell Histiocytosis

General Guidelines

- **Common sites of involvement include: bone, skin, lymph node, liver, spleen, oral mucosa, lung, and CNS.**

Simulation and Treatment Planning

- **CT simulation and conformal treatment planning is recommended for accurate target delineation and normal tissue sparing.**
- **Modalities: Intensity-modulated RT (IMRT) may be used in clinical settings where reduction in dose to organs at risk is required, which cannot be achieved by three-dimensional (3D) techniques. Electrons may be appropriate for skin lesions.**
- **Image-guided RT (IGRT) is a method that may be utilized to improve accuracy of radiation treatment delivery, when integrated with advanced techniques.**
- **Immobilization: Customized immobilization (ie, thermoplastic masks, Vacloc bags) should be used to minimize motion.**
- **Four-dimensional CT (4D-CT) planning or other motion management is recommended for lesions in regions subject to motion (ie, lung) to account for respiratory and organ movement.**
- **Target volumes should be defined based on imaging and clinical assessment.**

Target Volume (General Guidelines)

- **Preoperative and Postoperative[1,2]**
  - **Target volume determination may include MRI, CT, physical exam, postoperative reports, and pathology reports.**
    - **Target volumes:**
      - **Gross tumor volume (GTV): Defined by gross/residual disease if present.**
      - **Clinical target volume (CTV): Includes potential microscopic disease spread based on anatomical and histologic considerations.**
      - **Planning target volume (PTV): Expansion based on setup uncertainties and motion management.**

Normal Tissue Tolerance Dose-Limits

- **Dose constraints should prioritize sparing of normal tissues while maintaining tumor control.**

RT Dosing

- **There exists a wide range of experience with treatment doses, and reports using RT have shown favorable rates of local control.**

References

[1] Selch MT, Parker RG. Radiation therapy in the management of Langerhans cell histiocytosis. Med Pediatr Oncol 1990;18:97-102.

[2] Laird J, Ma J, Chau K, et al. Outcome after radiation therapy for Langerhans cell histiocytosis is dependent on site of involvement. Int J Radiat Oncol Biol Phys 2018;100:670-678.

Note: All recommendations are category 2A unless otherwise indicated.

Version 2.2025, 11/21/25 © 2025 National Comprehensive Cancer Network® (NCCN®), All rights reserved. NCCN Guidelines® and this illustration may not be reproduced in any form without the express written permission of NCCN.

PLEASE NOTE that use of this NCCN Content is governed by the End-User License Agreement, and you MAY NOT distribute this Content or use it with any artificial intelligence model or tool.
Printed by Máximo López Chenlo on 5/4/2026 6:21:12 PM. Copyright © 2026 National Comprehensive Cancer Network, Inc. All Rights Reserved.

ABBREVIATIONS

3D	three-dimensional
4D-CT	four-dimensional computed tomography
ACTH	adrenocorticotropic hormone
ALPS	autoimmune lymphoproliferative syndrome
ANA	antinuclear antibody
ANCA	antineutrophil cytoplasmic antibody
AVP	arginine vasopressin
AXG	adult xanthogranuloma
CBC	complete blood count
CMML	chronic myelomonocytic leukemia
CNS	central nervous system
CTV	clinical target volume
E-ABR	electrical auditory brainstem response
ECD	Erdheim-Chester disease
ENT	ear, nose, and throat
ERCP	endoscopic retrograde cholangiopancreatography
FDG	fluorodeoxyglucose
FISH	fluorescence in situ hybridization
FSH	follicle-stimulating hormone
G6PD	glucose-6-phosphate dehydrogenase
GI	gastrointestinal
GTV	gross tumor volume
H&P	history and physical
HEENT	head, ears, eyes, nose, throat
HRCT	high-resolution computed tomography
IGF-1	insulin-like growth factor 1
IgG4	immunoglobulin G4
IGRT	image-guided radiation therapy
IHC	immunohistochemistry
IMRT	intensity-modulated radiation therapy
JXG	juvenile xanthogranuloma
LCH	Langerhans cell histiocytosis
LDCT	low-dose computed tomography
LFT	liver function test
LH	luteinizing hormone
MDP	methylene diphosphonate
MDS	myelodysplastic syndrome
MPN	myeloproliferative neoplasm
MS-LCH	multisystem Langerhans cell histiocytosis
NGS	next-generation sequencing
PCR	polymerase chain reaction
PFT	pulmonary function test
PTV	planning target volume
RDD	Rosai-Dorfman disease
RF	rheumatoid factor
Tc-99m	technetium-99m
TSH	thyroid-stimulating hormone
TTE	transthoracic echocardiogram
UVA	ultraviolet A
UVB	ultraviolet B

Version 2.2025, 11/21/25 © 2025 National Comprehensive Cancer Network® (NCCN®), All rights reserved. NCCN Guidelines® and this illustration may not be reproduced in any form without the express written permission of NCCN.

PLEASE NOTE that use of this NCCN Content is governed by the End-User License Agreement, and you MAY NOT distribute this Content or use it with any artificial intelligence model or tool.
Printed by Máximo López Chenlo on 5/4/2026 6:21:12 PM. Copyright © 2026 National Comprehensive Cancer Network, Inc. All Rights Reserved.

NCCN Categories of Evidence and Consensus	
Category 1	Based upon high-level evidence (≥1 randomized phase 3 trials or high-quality, robust meta-analyses), there is uniform NCCN consensus (≥85% support of the Panel) that the intervention is appropriate.
Category 2A	Based upon lower-level evidence, there is uniform NCCN consensus (≥85% support of the Panel) that the intervention is appropriate.
Category 2B	Based upon lower-level evidence, there is NCCN consensus (≥50%, but <85% support of the Panel) that the intervention is appropriate.
Category 3	Based upon any level of evidence, there is major NCCN disagreement that the intervention is appropriate.

All recommendations are category 2A unless otherwise indicated.

NCCN Categories of Preference	
Preferred	Interventions that are based on superior efficacy, safety, and evidence; and, when appropriate, affordability.
Other recommended	Other interventions that may be somewhat less efficacious, more toxic, or based on less mature data; or significantly less affordable for similar outcomes.
Useful in certain circumstances	Other interventions that may be used for selected patient populations (defined with recommendation).

All recommendations are considered appropriate.

Version 2.2025, 11/21/25 © 2025 National Comprehensive Cancer Network® (NCCN®), All rights reserved. NCCN Guidelines® and this illustration may not be reproduced in any form without the express written permission of NCCN.

PLEASE NOTE that use of this NCCN Content is governed by the End-User License Agreement, and you MAY NOT distribute this Content or use it with any artificial intelligence model or tool.
Printed by Máximo López Chenlo on 5/4/2026 6:21:12 PM. Copyright © 2026 National Comprehensive Cancer Network, Inc. All Rights Reserved.

Discussion

This discussion corresponds to the NCCN Guidelines for Histiocytic Neoplasms. Last updated: January 7, 2025.

Table of Contents

Overview **MS-2**
Guidelines Update Methodology **MS-2**
Literature Search Criteria **MS-2**
Sensitive/Inclusive Language Usage **MS-3**
Characteristics and Diagnostic Evaluation of Histiocytic Neoplasms **MS-3**
Pathologic Analysis of Histiocytic Neoplasms **MS-3**
Langerhans Cell Histiocytosis **MS-4**
Diagnosis of LCH MS-5
Histopathologic Characterization of LCH MS-6
Treatment of LCH MS-7
Unifocal and Single System Disease with No Critical Organ Involvement MS-7
Multisystem or Multifocal Single-System Disease or Unifocal Disease with Critical Organ Involvement or that Progresses on Local Therapy MS-7
Systemic Therapy for LCH MS-8
Follow-up MS-11
Treatment for Relapsed/Refractory Disease MS-11
Erdheim-Chester Disease **MS-11**
Diagnosis of ECD MS-12
Histopathologic Characterization of ECD MS-13
Treatment of ECD MS-14
Follow-up MS-15
Rosai-Dorfman Disease **MS-15**
Diagnosis of RDD MS-16
Histopathologic Characterization of RDD MS-17
Treatment of RDD MS-18
Systemic Therapy MS-18
Follow-up MS-19
Supportive Care for Patients **MS-19**
Summary **MS-20**
References **MS-21**

Discussion update in progress

Version 2.2025 © 2025 National Comprehensive Cancer Network© (NCCN©), All rights reserved. NCCN Guidelines® and this illustration may not be reproduced in any form without the express written permission of NCCN.

PLEASE NOTE that use of this NCCN Content is governed by the End-User License Agreement, and you MAY NOT distribute this Content or use it with any artificial intelligence model or tool.
Printed by Máximo López Chenlo on 5/4/2026 6:21:12 PM. Copyright © 2026 National Comprehensive Cancer Network, Inc. All Rights Reserved.

Overview

Histiocytic neoplasms represent hematologic disorders characterized by the accumulation of myeloid-dendritic cell-derived neoplastic cells with an accompanying inflammatory infiltrate.[1,2] They are rare, accounting for less than 1% of cancers of the soft tissue and lymph nodes.[2] Histiocytic neoplasms are also heterogeneous, and presentation varies from localized and mild to disseminated and lethal.[1] Initial presentation is often nonspecific, which can lead to a significant delay in the diagnosis and treatment of histiocytic disorders,[3] and these patients should ideally be evaluated and treated at centers of expertise.

There are over 100 subtypes of histiocytoses.[1] The original classification of histiocytic neoplasms by the Working Group of the Histiocyte Society, which was published in 1987, categorized these disorders as follows: Langerhans cell, non-Langerhans cell, and malignant histiocytoses.[4] However, this categorization of histiocytic neoplasms as Langerhans/non-Langerhans was not useful, as neoplasms classified as Langerhans cell histiocytosis (LCH) were found to share many of the same molecular features as those classified as Erdheim-Chester disease (ECD), following emerging deep sequencing diagnostic methods.[1,2] For example, clonal mutations of genes in the MAPK pathway have been found in the majority of Langerhans and non-Langerhans histiocytoses.[5-8] Thus, in 2016, the Histiocyte Society published a revised classification based on clinical, radiographic, histologic, phenotypic, and other molecular features, further dividing them into five groups of diseases: 1) Langerhans-related; 2) cutaneous and mucocutaneous; 3) malignant histiocytoses; 4) Rosai-Dorfman disease (RDD); and 5) hemophagocytic lymphohistiocytosis and macrophage activation syndrome.[1]

The NCCN Clinical Practice Guidelines (NCCN Guidelines®) for Histiocytic Neoplasms include recommendations for the diagnosis and treatment of adults with LCH, ECD, and RDD, which are the most commonly seen histiocytic neoplasms in adults. The evidence supporting the management of histiocytic neoplasms in adults is largely based on small retrospective studies, case series, and case reports, due to the paucity of prospective studies in adults. In addition, some of the diagnostic and treatment recommendations for adults with histiocytic neoplasms are, out of necessity, extrapolated from prospective studies in children and young adults, except when stated otherwise.

Guidelines Update Methodology

The complete details of the Development and Update of the NCCN Guidelines are available at www.NCCN.org.

Literature Search Criteria

Prior to the annual update of the NCCN Guidelines® for Histiocytic Neoplasms, an electronic search of the PubMed database was performed to obtain key literature published since the previous update, using the search terms: (histiocyt* OR ("Langerhans cell") OR (Erdheim-Chester) OR (Rosai-Dorfman)) AND (cancer OR oncology OR neoplasm). The PubMed database was chosen because it remains the most widely used resource for medical literature and indexes peer-reviewed biomedical literature.[9]

The search results were narrowed by selecting studies in humans published in English. Results were confined to the following article types: Clinical Trial, Phase II; Clinical Trial, Phase III; Clinical Trial, Phase IV; Guideline; Practice Guideline; Randomized Controlled Trial; Meta-Analysis; Systematic Reviews; and Validation Studies. The data from key PubMed articles as well as articles from additional sources deemed relevant to these guidelines as discussed by the Panel have been included in this version of the Discussion section.

Discussion update in progress

Version 2.2025 © 2025 National Comprehensive Cancer Network© (NCCN©), All rights reserved. NCCN Guidelines® and this illustration may not be reproduced in any form without the express written permission of NCCN.

PLEASE NOTE that use of this NCCN Content is governed by the End-User License Agreement, and you MAY NOT distribute this Content or use it with any artificial intelligence model or tool.
Printed by Máximo López Chenlo on 5/4/2026 6:21:12 PM. Copyright © 2026 National Comprehensive Cancer Network, Inc. All Rights Reserved.

Recommendations for which high-level evidence is lacking are based on the Panel's review of lower-level evidence and expert opinion.

Sensitive/Inclusive Language Usage

NCCN Guidelines strive to use language that advances the goals of equity, inclusion, and representation.[10] NCCN Guidelines endeavor to use language that is person-first; not stigmatizing; anti-racist, anti-classist, anti-misogynist, anti-ageist, anti-ableist, and anti-weight-biased; and inclusive of individuals of all sexual orientations and gender identities. NCCN Guidelines incorporate non-gendered language, instead focusing on organ-specific recommendations. This language is both more accurate and more inclusive and can help fully address the needs of individuals of all sexual orientations and gender identities. NCCN Guidelines will continue to use the terms men, women, female, and male when citing statistics, recommendations, or data from organizations or sources that do not use inclusive terms. Most studies do not report how sex and gender data are collected and use these terms interchangeably or inconsistently. If sources do not differentiate gender from sex assigned at birth or organs present, the information is presumed to predominantly represent cisgender individuals. NCCN encourages researchers to collect more specific data in future studies and organizations to use more inclusive and accurate language in their future analyses.

Characteristics and Diagnostic Evaluation of Histiocytic Neoplasms

Characteristics of LCH, ECD, and RDD involve features across multiple organ systems, including the bone, nervous, endocrine, respiratory, dermatologic, and cardiac systems, among others.[3] These diverse clinical manifestations mimic other conditions, posing a major diagnostic challenge. For a more detailed list of characteristic features of ECD, LCH, and RDD, see *Characteristic Features of Histiocytic Neoplasms* in the algorithm.

For patients with suspected disease, a complete medical history and physical (H&P) examination should be conducted along with laboratory tests, including a complete blood count (CBC) with differential, a comprehensive metabolic panel that includes liver and kidney function assessments, evaluation of C-reactive protein, morning urine and serum osmolality, morning serum cortisol with adrenocorticotropic hormone (ACTH), thyroid-stimulating hormone (TSH) plus free T4, follicle-stimulating hormone/luteinizing hormone (FSH/LH) with testosterone or estradiol, and prolactin and insulin-like growth factor 1. A bone marrow aspirate/biopsy should be performed if the patient has an abnormal, unexplained CBC, and, if brain lesions are present but inaccessible by biopsy, a lumbar puncture should also be conducted. Subspecialty consultations (eg, pulmonary and smoking cessation, neurology, endocrinology) should be carried out as clinically indicated. Dermatology consultation is recommended for patients treated with certain targeted therapies (ie, BRAF and MEK inhibitors) for diagnosis and treatment of skin-related toxicities.[11] Retinal evaluation may be considered due to the high incidence of serious retinopathy with MEK inhibitors.[12,13] See *Principles of Diagnostic Evaluation* in the algorithm for a full assessment list.

Pathologic Analysis of Histiocytic Neoplasms

Immunohistochemical (IHC) analysis plays an important role in the diagnosis of histiocytic neoplasms and should be carried out when a histiocytic neoplasm is suspected. The basic IHC panel should include CD163/CD68, S100, CD1a, Langerin/CD207, cyclin D1, and factor XIIIa as indicated.[3] *BRAF* V600E (VE1) IHC is recommended for LCH and ECD. It should be noted that negative or equivocal IHC for *BRAF* V600E VE1 does not exclude mutated *BRAF* V600E and further testing

Discussion update in progress

Version 2.2025 © 2025 National Comprehensive Cancer Network© (NCCN©), All rights reserved. NCCN Guidelines® and this illustration may not be reproduced in any form without the express written permission of NCCN.

PLEASE NOTE that use of this NCCN Content is governed by the End-User License Agreement, and you MAY NOT distribute this Content or use it with any artificial intelligence model or tool.
Printed by Máximo López Chenlo on 5/4/2026 6:21:12 PM. Copyright © 2026 National Comprehensive Cancer Network, Inc. All Rights Reserved.

may be required. Anaplastic lymphoma kinase (ALK) and fascin may also be included as clinically indicated to identify *ALK*-rearranged histiocytoses.[14] IHC analysis can be helpful in the broad differential diagnosis of histiocytosis, including varied entities such as composite IgG4-related disease and B-cell lymphoma, as well as infection, fat necrosis, and idiopathic retroperitoneal fibrosis.[3]

Next-generation sequencing (NGS) of fresh or paraffin-embedded tumor tissue for identification of mutations in the RAS/RAF/MAPK/ERK and PI3K/AKT pathway genes can be instrumental in the diagnosis of histiocytic neoplasms and can also inform systemic therapy decision-making.[3] Peripheral blood may be informative of multisystem disease. Additionally, fusion testing should be performed to assess for *BRAF*, *ALK*, *RET*, and *NTRK1* rearrangements. Of note, fusion testing is recommended if histiocytosis is clinically suspected and the NGS panel does not reveal *BRAF* or other MAPK mutations.[15] If fusion panel testing is unavailable, then IHC or fluorescence in situ hybridization (FISH) may be used to evaluate for *ALK* rearrangements. Molecular testing can be done either in a stepwise fashion or in parallel, depending on clinical indication and institutional protocols. If a specific histiocytic disorder is suspected, then stepwise testing should be tailored based on the mutations known to be associated with that disorder.[15] Further details regarding recommendations for pathologic analysis related to LCH, ECD, and RDD are included below. A complete list of immunophenotypes and molecular features to include in the evaluation can also be found on the *Summary of Pathologic and Molecular Features of Histiocytic Neoplasms* pages in the algorithm.

Langerhans Cell Histiocytosis

LCH is the most common histiocytic disorder and occurs more frequently in children than adults. The incidence of disseminated LCH is estimated to be 5 to 9 cases per 1 million in children (>15 years) and 0.07 cases per 1 million in adults (>18 years).[16-18] A study examining SEER registry data in the United States showed that 5-year overall survival for adults with LCH was 88.5%, but, while many cases are mild and asymptomatic, rapidly progressing and/or disseminated life-threatening disease that is resistant to treatment may also occur.[19] The Histiocyte Society's initial 1987 classification categorized LCH as an immunologic inflammatory disease but not as a neoplasm.[4] However, presence of clonal histiocytes supports the neoplastic origin of LCH.[20,21] Recurrent activating mutations in the MAPK pathway are found in the vast majority of cases.[8,22] These discoveries support the WHO's classification of histiocytic disorders, particularly LCH as a neoplastic process.[23] In the Histiocyte Society's revised classification, four categories of LCH are identified: single system, pulmonary-involved, multisystem with risk organ involvement, and multisystem without risk organ involvement.[1]

Common sites of involvement of LCH include bone, skin, pituitary gland, liver, spleen, bone marrow, lungs, and lymph nodes.[24] There is also a high prevalence of concomitant and subsequent malignancies, especially solid tumors or myeloid malignancies, in adults with LCH.[18,25] A pulmonary form of LCH can occur in adults and is associated with smoking.[21,26,27] Multifocal bone lesions without the involvement of other organs may also be observed in some cases, and bone mineral density may be lower than the expected range in adults with LCH.[28] Permanent endocrinopathy is common in LCH, such as diabetes insipidus (now referred to arginine vasopressin [AVP] deficiency), which more commonly occurs with multisystem disease.[21,29,30] Though there are cases of solitary central nervous system (CNS)-involved LCH, CNS involvement is most often accompanied with multi-system disease.[24] CNS-involved LCH can present as space-occupying granulomatous tumors, frequently in the hypothalamic-pituitary region but also involving the choroid plexus, meninges, grey or white matter, or as

Discussion update in progress

Version 2.2025 © 2025 National Comprehensive Cancer Network© (NCCN©), All rights reserved. NCCN Guidelines® and this illustration may not be reproduced in any form without the express written permission of NCCN.

PLEASE NOTE that use of this NCCN Content is governed by the End-User License Agreement, and you MAY NOT distribute this Content or use it with any artificial intelligence model or tool.
Printed by Máximo López Chenlo on 5/4/2026 6:21:12 PM. Copyright © 2026 National Comprehensive Cancer Network, Inc. All Rights Reserved.

neurodegenerative LCH (ND-LCH) lesions in the cerebellum and brain stem.[31] The bone lesions in the mastoid, sphenoid, orbit, temporal bone, and clivus represent CNS-risk lesions, indicating increased risk of developing CNS-involved LCH.[31] ND-LCH is frequent in patients with pituitary, skin, and base-of-skull bone involvement. A study of children and young adults with LCH (N = 1897) showed that a *BRAF* mutation was present in 93.7% of patients with ND-LCH, compared to 54.1% in patients without ND-LCH.[32] The 10-year risk of developing neurodegenerative disease is 33.1% in patients with a *BRAF* mutation, compared to 2.9% in patients without a *BRAF* mutation (P = .002).

Diagnosis of LCH

Initial diagnostic testing is dependent on clinical presentation. Essential workup for LCH involves a comprehensive H&P examination with specific attention to common sites of involvement, including the skin; head, eyes, ears, nose, and throat (HEENT); bone, lymph node, liver, spleen, lung, and CNS.[21,33] Whole-body fluorodeoxyglucose (FDG)-PET/CT, including distal extremities, should be performed along with pulmonary function tests (PFTs) to evaluate for obstructive airway disease, air trapping, and carbon monoxide diffusing capacity.[21,26] FDG-PET/CT is superior to other cross-sectional imaging techniques for detection of sites of active LCH, with the exception of pulmonary lesions.[34-36] Bone involvement, which may appear as aggressive cortically-based lytic lesions, is also best detected using full-body (vertex-to-toes) FDG-PET/CT.[3] It is controversial whether whole-body imaging is required for every patient with LCH, such as those presenting only with skin involvement, or those with symptoms limited to the lungs. However, whether a patient's LCH is single or multisystem is unknown in the absence of imaging and should be considered for patients with suspected multisystem disease. High-resolution CT of the chest for suspected pulmonary LCH is recommended as it[33] may detect nodules ≤2 mm in the early stages of pulmonary LCH, and irregular cysts in the lungs may be observed in advanced disease.[3,21] Laboratory tests, including those mentioned in the earlier *Characteristics and Diagnostic Evaluation of Histiocytic Neoplasms* section of this Discussion, are also part of the essential workup for LCH.[21,33]

Further workup may be useful depending on symptoms or organ involvement. Additional imaging can be conducted including: CT with contrast of the chest, abdomen, and pelvis and MRI with and without contrast of the brain, spine, and sella turcica with or without pituitary evaluation, if AVP deficiency is suspected. Abnormal brain MRI is often observed in LCH, even in the absence of neurologic symptoms.[24] Findings on brain MRI can mimic primary CNS tumors, brain metastases, or inflammatory granulomatous diseases.[24] In ND-LCH, signal changes in white and deep gray matter with cortical atrophy may be observed with MRI.[31] In cases that manifest with AVP deficiency, the earliest change seen on MRI may be an enlargement of the pituitary stalk, and later the space-occupying tumors extending to the pituitary gland and hypothalamus. There is typically a ''loss of bright spot'' (ie, the lack of the physiologic hyperintense signal in the posterior pituitary on T1-weighted images), which is secondary to the loss of antidiuretic hormone-containing granules. Not all patients with AVP deficiency will have an abnormal MRI.

Ultrasound of the abdomen allows for determination of hepatic and spleen involvement, and other imaging techniques such as endoscopic retrograde cholangiopancreatography and digital panoramic dental x-ray can also be performed as clinically indicated. Right heart catheterization should be performed if pulmonary hypertension is suspected, and transthoracic echocardiogram (TTE) is also recommended to screen for pulmonary hypertension.[3] Endocrine evaluation is encouraged for those with detected endocrinopathy or pituitary hypothalamic involvement. Comprehensive neurocognitive and

Discussion update in progress

Version 2.2025 © 2025 National Comprehensive Cancer Network© (NCCN©), All rights reserved. NCCN Guidelines® and this illustration may not be reproduced in any form without the express written permission of NCCN.

PLEASE NOTE that use of this NCCN Content is governed by the End-User License Agreement, and you MAY NOT distribute this Content or use it with any artificial intelligence model or tool.
Printed by Máximo López Chenlo on 5/4/2026 6:21:12 PM. Copyright © 2026 National Comprehensive Cancer Network, Inc. All Rights Reserved.

psychological assessments should be included for select patients.[21] The complete recommendations for evaluation of LCH are provided in the algorithm (see *Langerhans Cell Histiocytosis: Workup/Evaluation*) and are adapted from recommendations in the consensus statement by the Mayo Clinic Histiocytosis Working Group[3]

While diagnosis of LCH is based on clinical and radiologic findings, biopsy of tumor tissue is also recommended (see *Histopathologic Characterization of LCH* below in this Discussion).[21] Morphologically, in LCH, histiocytes with grooved nuclei are observed along with eosinophilia. IHC analysis of tumor tissue, which should include a minimal panel of CD1a, S100, and Langerin as well as cyclin D1 and *BRAF* V600E VE1 IHC, is recommended at this time along with NGS and gene fusion assays to evaluate for somatic genetic variants of the MAPK and other related pathways (see *Histopathologic Characterization of LCH* below for more information). If biopsy is not possible due to location or other risk factors, mutational analysis of peripheral blood is an option. If a patient has an unexplained, abnormal CBC, a bone marrow biopsy should also be considered to rule out hemophagocytic lymphohistiocytosis or myeloid neoplasm. Because LCH frequently presents with lytic bone lesions, differential diagnosis may include multiple myeloma and metastatic bone involvement from other cancers. Skin involvement may be mistaken for seborrheic dermatitis, eczema, psoriasis, Candida infection, intertrigo, and lichen planus.[21] Langerhans cell hyperplasia can be associated with mycosis fungoides, which could be misinterpreted as a composite LCH.[37] Differential diagnosis for single-system pulmonary LCH includes hypersensitivity pneumonitis, interstitial pneumonia, pulmonary lymphangioleiomyomatosis, and sarcoidosis.

Histopathologic Characterization of LCH

Cytologic features typically observed with LCH include an oval-shaped nucleus that is retiform with irregular nuclear contours, an inconspicuous nucleoli, and abundant cytoplasm.[15] On hematoxylin and eosin (H&E) stain, neoplastic LCH cells are mononucleated, typically with a coffee bean-shaped nucleus.[1,22,38] LCH tumors often demonstrate neoplastic histiocytes admixed with marked inflammatory cell infiltration. Abundant eosinophils and multinucleated giant cells are frequently observed.[1-3] Pathology of lesions from LCH-associated abnormal CNS imaging (LACI) and LCH-associated abnormal CNS symptoms (LACS) show infiltrating CD8+ lymphocytes, and, unlike other LCH tumors, lack CD1a-positive histiocytes.[39] Birbeck granules can be identified by electron microscope, which is, however, now not commonly performed. Fibrosis may be present, particularly in bone lesions.[3]

IHC analysis of LCH tumors demonstrates abundant CD1a- and CD207- (Langerin) positive neoplastic histiocytes that are also positive for S100 and cyclin D1.[3,22,38] Cyclin D1 can be helpful for differentiating neoplastic Langerhans cells from reactive Langerhans cell proliferation.[40,41] Activation of RAS-RAF-MAPK pathway is universal in all patients with LCH.[5,42] A *BRAF* V600E activating mutation is the most prevalent, presenting in 38% to 64% of LCH cases, and carries prognostic significance. [5,6,43-47] This mutation is more frequent in mixed LCH/ECD, when compared to isolated LCH or ECD.[48] Thus, *BRAF* V600E (VE1) should also be evaluated using IHC. However, studies evaluating IHC versus PCR testing of *BRAF* V600E mutations in pediatric patients with LCH (using stringent scoring criteria[49]) showed sensitivity values ranging from 35.6% to 80%; specificity values ranged from 75.5% to 100%.[50,51] *BRAF* V600E allele-specific PCR is recommended if IHC is unavailable or when *BRAF* V600E (VE1) IHC results are equivocal or negative. Mutations in *MAP2K1/2* are also prevalent in LCH (~20%) and are mutually exclusive with *BRAF* V600E

Discussion update in progress

Version 2.2025 © 2025 National Comprehensive Cancer Network© (NCCN©), All rights reserved. NCCN Guidelines® and this illustration may not be reproduced in any form without the express written permission of NCCN.

PLEASE NOTE that use of this NCCN Content is governed by the End-User License Agreement, and you MAY NOT distribute this Content or use it with any artificial intelligence model or tool.
Printed by Máximo López Chenlo on 5/4/2026 6:21:12 PM. Copyright © 2026 National Comprehensive Cancer Network, Inc. All Rights Reserved.

mutations.[8,43,47,52] *KRAS*, *NRAS*, *ARAF*, and *CSF1R* mutations are less frequently observed in LCH.[15,53] Therefore, evaluation of tumor tissue by NGS to determine somatic variants in the MAPK pathway genes (*BRAF*, *ARAF*, *NRAS*, *KRAS*, *MAP2K1/2*) and other related pathway mutations, such as *PIK3CA* and *CSF1R*, along with gene fusion assays that cover *BRAF*, *ALK*, *RET*, and *NTRK1* rearrangements, are recommended. ALK IHC and FISH studies can be used if there is a concern for *ALK* rearrangement and fusion panel testing is not available. For complete recommendations regarding pathologic analysis of LCH cases, see the *Principles of Pathology* section in the algorithm.

Treatment of LCH

Much of the evidence for treatment of LCH is extrapolated from prospective studies of children and adolescents. Studies of adults with LCH are limited to case series and retrospective studies. Treatment decisions for LCH should be made based on sites and extent of disease.[21]

Unifocal and Single System Disease with No Critical Organ Involvement

For patients with single system disease and no involvement of critical organs (ie, CNS, liver, spleen), treatment is limited to local therapy (surgical excision or RT) and observation.[21]

Limited curettage is recommended for patients with isolated bone lesions,[54] but complete resection of bone lesions is not recommended, as this may result in an increase in the size of the bony defect and permanent skeletal defects.[21] Corticosteroid injection, with triamcinolone or equivalent, may facilitate healing after limited curettage.[21] Low-dose radiation therapy for treatment of bone-involved LCH is associated with excellent local disease control.[55,56] For patients with single system bone disease, radiation therapy may be used for some patients with limited sites of disease, specifically in cases with impending neurologic dysfunction and if surgical risk is high.[21] “Limited” sites of disease is generally defined as 1 to 2 lesions in this context, though radiation therapy may be considered for up to three bone lesions as clinically indicated. The recommended radiation dose for treatment of bone-involved LCH in adults is 10 to 20 Gy.[21,55] Bisphosphonate therapy is preferred if bone lesions are not amenable to local therapies due to size and location (See *Principles of Systemic Therapy* in the algorithm). Observation is also reasonable for asymptomatic and isolated bone lesions.

For patients with single system isolated skin disease, topical therapies may be used.[54] Case reports describing treatment of older adults with cutaneous LCH support the use of psoralen with ultraviolet A (PUVA) or narrowband ultraviolet B (UVB).[57,58] Other topical therapies such as nitrogen mustard (eg, mechlorethamine) and steroids (triamcinolone injection or equivalent corticosteroid) are alternative options that have been shown to be effective in children with cutaneous LCH,[59,60] though there are no published data in adults with LCH. Surgery should only be performed for solitary skin lesions, and only for those in which surgery will not result in disfigurement. Low-dose RT is also an option for these patients, and systemic therapy may be used for symptomatic disease including pain, secondary infection, or if there are complications from skin lesions.[54] Isolated skin-involved LCH has been reported to resolve spontaneously,[61] so observation is also an option for these patients.

Multisystem or Multifocal Single-System Disease or Unifocal Disease with Critical Organ Involvement or that Progresses on Local Therapy

Systemic therapy is often required for the treatment of multisystem LCH, multifocal single system LCH, unifocal disease involving a critical organ such as CNS, liver, spleen, or unifocal disease that progresses on local therapy (see *Systemic Therapy for LCH*, described below). However, if asymptomatic or if there is no impending organ dysfunction, observation may be considered. Imaging changes precede clinical

Discussion update in progress

Version 2.2025 © 2025 National Comprehensive Cancer Network© (NCCN©), All rights reserved. NCCN Guidelines® and this illustration may not be reproduced in any form without the express written permission of NCCN.

PLEASE NOTE that use of this NCCN Content is governed by the End-User License Agreement, and you MAY NOT distribute this Content or use it with any artificial intelligence model or tool.
Printed by Máximo López Chenlo on 5/4/2026 6:21:12 PM. Copyright © 2026 National Comprehensive Cancer Network, Inc. All Rights Reserved.

progression in ND-LCH, warranting consideration of early treatment, and cognitive symptoms should be carefully evaluated and monitored. Bisphosphonates (eg, zoledronic acid or pamidronate) are recommended for treatment of multifocal bone disease, which is supported by small retrospective studies and case series.[62,63] In the absence of disease response following treatment with a bisphosphonate, other systemic therapy regimens may be considered (see *Systemic Therapy for LCH*, described below). Radiation therapy can also be considered in patients with persistent disease with limited disease sites following systemic treatment.[21,64]

Since pulmonary LCH is associated with smoking, treatment should include smoking cessation (see the NCCN Guidelines for Smoking Cessation, available at www.NCCN.org). Pulmonary LCH could resolve with smoking cessation alone.[54] Therefore, observation is an option, particularly in patients with asymptomatic disease or who have minor symptoms. Systemic therapy can be considered in patients with symptomatic and/or progressive pulmonary LCH, as well as in patients with persistent disease despite smoking cessation (see *Systemic Therapy for LCH*, described below). High-dose prednisone (1 mg/kg/day for 1 month, followed by a slow taper) can also be effective in treatment of pulmonary LCH.[21] Steroid treatment is often associated with radiographic improvements in pulmonary LCH but may not improve the respiratory function.[65] Lung transplant should be considered only in select patients with highly refractory and severe disease.[54]

Systemic Therapy for LCH

Systemic therapy is the standard treatment in the first- or subsequent-line settings for multisystem and/or multifocal LCH, but responses to commonly used regimens in adults with LCH tend to be less robust compared to children. Preferred systemic therapy regimens for multisystem or single-system lung LCH and LCH CNS lesions currently include vemurafenib for *BRAF* V600E mutated disease, cobimetinib for patients with MAP kinase pathway mutation, no other detectable/actionable mutation, or if testing is not available, and cytarabine or cladribine, irrespective of mutation.

Prior to 2012, there were relatively few effective treatment options for histiocytic neoplasms. The discovery of *BRAF* V600E and other gene mutations resulting in overactive MAPK pathway in histiocytic neoplasms led to a promising avenue of targeted therapies for patients with these rare cancers. The phase II VE-BASKET study evaluated the efficacy of BRAF inhibitor vemurafenib.[66] The final efficacy and safety analysis included 26 adults with *BRAF* V600E-mutated LCH or ECD (85% ECD) and showed an overall response rate (ORR) of 61.5% (95% CI, 40.6%–79.8%).[67] Two-year progression-free survival (PFS) and overall survival (OS) rates were 86% (95% CI, 72%–100%) and 96% (95% CI, 87%–100%), respectively. Median PFS and OS were not reached. A metabolic response as measured with FDG-PET/CT was achieved in all of the patients who were evaluated (n = 15; 80% complete response [CR], 20% partial response [PR]). The most common grade 3–4 adverse events were hypertension (27%), maculopapular rash (23%), increased lipase (15%), arthralgia (12%), hyperkeratosis (8%), and actinic keratosis (8%). All patients required dose reduction due to toxicities.

There is also evidence supporting the use of MEK inhibitors for treatment of histiocytic neoplasms. The MEK inhibitor cobimetinib was evaluated in a phase II trial including 18 adult patients diagnosed with a histiocytic neoplasm (67% ECD, 11% LCH, 11% RDD, and 11% mixed histiocytosis).[12] The ORR was 89% (one-sided 90% CI, 73%–100%), with a CR having been observed in 72% of patients. Median duration of response (DOR) and PFS were not reached after a median follow-up of 11.9 months. The most common adverse events that led to a dose

Discussion update in progress

Version 2.2025 © 2025 National Comprehensive Cancer Network© (NCCN©), All rights reserved. NCCN Guidelines® and this illustration may not be reproduced in any form without the express written permission of NCCN.

PLEASE NOTE that use of this NCCN Content is governed by the End-User License Agreement, and you MAY NOT distribute this Content or use it with any artificial intelligence model or tool.
Printed by Máximo López Chenlo on 5/4/2026 6:21:12 PM. Copyright © 2026 National Comprehensive Cancer Network, Inc. All Rights Reserved.

reduction were ejection fraction decrease (27.8%), rash (11.1%), and diarrhea (11.1%). Though a mutation in the MAPK pathway was detected in 83% of patients, the efficacy of cobimetinib was not limited to these patients, indicating that cobimetinib can be used in any patient with a histiocytic disorder for whom systemic therapy is indicated. Adverse events in patients with histiocytic disorders treated with BRAF and MEK inhibitors are consistent with those observed in previously published studies (eg, rash, pyrexia),[22] but the VE-BASKET trial showed that rates of hypertension and skin-related adverse events were higher in histiocytic neoplasms than previously observed in patients with metastatic melanoma.[67]

Cladribine is a chemotherapy option that has been shown to be active in adults with LCH. A recent single-center phase II trial of 61 newly diagnosed adults with LCH revealed an ORR of 93.4% with 20 patients achieving a complete response and 37 demonstrating a partial response.[68] Moreover, the estimated 3-year OS and EFS were 100% and 58.8%, respectively.[68] Neutropenia, thrombocytopenia, and nausea were the most common grade 3–4 toxicities.[68] However, for patients who received cladribine as part of single-center retrospective study in 58 patients with bone-involved LCH, 59% did not respond to treatment or relapsed in the first year while the chemotherapy, cytarabine, showed lower toxicity with grade 3–4 adverse events being reported in 20% of patients who received cytarabine, compared to 37% who received cladribine. Low-dose cytarabine is better tolerated in adults, but higher doses should be used for patients with CNS lesions.

Other recommended regimens for patients with multisystem or single-system lung LCH or CNS lesions include: dabrafenib for *BRAF* V600E-mutated disease, trametinib, binimetinib, or selumetinib for MAP kinase pathway mutation or no other detectable/actionable mutation, or for those for whom testing was not available. Encouraging results from a case series support the use of dabrafenib, a second-generation BRAF inhibitor, in adults with LCH. Dabrafenib may be better tolerated than vemurafenib based on this case series, although there was no prospective head-to-head comparison.[69] Use of dabrafenib in patients with ND-LCH led to rapid symptomatic and radiographic improvement. Use of the MEK inhibitor trametinib for treatment of LCH is supported by case series and case reports.[70-72] In one case report, a combination of dabrafenib and trametinib demonstrated a sustained response in an adult woman with *BRAF* V600E-mutated LCH.[73] Binimetinib or selumetinib are recommended if neither cobimetinib or trametinib are not tolerated.

Methotrexate plus cytarabine, hydroxyurea, clofarabine, vinblastine/prednisone, or oral methotrexate, are also other recommended regimens for patients with multisystem or single-system lung LCH, irrespective of mutation while high-dose methotrexate or methotrexate plus cytarabine are other recommended regimens for patients with CNS lesions. A prospective single-center phase II trial from China examined combination of cytarabine (100 mg/m^2) and methotrexate (1 g/m^2) as treatment for adults with multisystem or single system multifocal LCH (N = 83). ORR, 3-year OS, and 3-year event-free survival (EFS) were 87.9%, 97.7%, and 68.0%, respectively.[74] The long-term follow-up of this study recently indicated that, after a median follow-up of 6.5 years, the ORR, 6-year OS, and 6-year EFS were 89.5%, 93.2%, and 55.2%, respectively.[75] Additionally, a retrospective study conducted at a hospital in China examined cytarabine and methotrexate combination in adults with multisystem pulmonary-involved LCH (N = 29). Pulmonary function was stable in 72.4% (n = 24), improved in 13.8% (n = 4), and deteriorated in 13.8% (n = 4) of patients.[76] Since both cytarabine and methotrexate cross the blood-brain barrier, this combination regimen may be ideal for treatment of CNS-involved LCH.[74] Vinblastine plus prednisone is the preferred

Discussion update in progress

Version 2.2025 © 2025 National Comprehensive Cancer Network© (NCCN©), All rights reserved. NCCN Guidelines® and this illustration may not be reproduced in any form without the express written permission of NCCN.

PLEASE NOTE that use of this NCCN Content is governed by the End-User License Agreement, and you MAY NOT distribute this Content or use it with any artificial intelligence model or tool.
Printed by Máximo López Chenlo on 5/4/2026 6:21:12 PM. Copyright © 2026 National Comprehensive Cancer Network, Inc. All Rights Reserved.

chemotherapy-based treatment for LCH in the pediatric setting.[22] In a retrospective study conducted at a single center including 58 adults with bone-involved LCH, use of vinblastine and prednisone was associated with worse outcomes. In this study, 84% of patients who received vinblastine and prednisone developed progressive disease within the first year, compared to 21% of patients who received cytarabine (OR, 20.3; 95% CI, 4.20–98.20; $P < .001$).[77] There is also evidence supporting clofarabine for relapsed/refractory LCH in the pediatric setting, with disease improvement observed in 73% of 11 patients.[78] Neutropenia occurred in all patients.

High-dose methotrexate is also an option for CNS-involved LCH, based on a case report of a patient with CNS-involved ECD while low-dose oral methotrexate has been shown to be effective and non-toxic in a case report of a 40-year-old patient with LCH, which was also supported in children treated with low-dose methotrexate plus prednisone for low-risk LCH.[79-81] In addition, hydroxyurea demonstrated promising activity with 80% of patients demonstrating either a PR or CR with minimal toxicities.[82]

Targeted therapies may be useful in certain circumstances for patients with multisystem or single system lung LCH or CNS lesions and include: crizotinib for *ALK* fusion, pexidartinib for *CSF1R* mutation, larotrectinib, entrectinib, or repotrectinib for *NTRK* gene fusions, sirolimus or everolimus for *PIK3CA* mutation, or selpercatinib for *RET* fusion. Activating mutations in *CSF1R* and rearrangements involving *RET* and *ALK* in rare cases of LCH highlight the potential clinical benefit of other kinase inhibitors and should be considered in select cases with such alterations.[53] Since *NTRK* fusions can occur in histiocytic disorders,[83] the TRK inhibitors larotrectinib,[84] entrectinib,[85] and repotrectinib[86] may also be used as indicated. Sirolimus and everolimus can be effective for *PIK3CA*-mutated LCH, based on extrapolation of data from patients with ECD (see *Treatment of ECD* in this Discussion, below).[7,87] It is of note that targeted therapies can be started at lower doses. Additionally, allogeneic hematopoietic cell transplant is recommended for highly select patients with multisystem or single-system lung LCH.[88]

For bone disease only LCH, preferred regimens include bisphosphonates, which were discussed earlier in this Discussion. For multifocal single-system bone disease not responsive to bisphosphonates, the preferred, other recommended and useful in certain circumstances options mentioned earlier in this Discussion for multisystem disease can be considered.

Single-system multifocal skin disease can be treated with oral methotrexate or hydroxyurea (both preferred regimens) or lenalidomide or thalidomide (both other recommended regimens). Small retrospective studies and case reports support this use of specific chemotherapy options for multifocal skin-involved LCH. A single-center retrospective study evaluated hydroxyurea monotherapy and in combination with oral methotrexate in 15 patients with relapsed/refractory LCH (mostly skin-involved) with a median age of 41.2 years (range, 2–73 years).[82] An ORR of 80.0% was observed, and symptom progression or relapse after initial response was observed in 40%, with median time to progression of 5.7 months. Grade 3–4 adverse events were reported in only two patients. Retrospective data also support use of oral methotrexate combined with prednisone in children with low-risk LCH (ie, no bone marrow involvement or organ dysfunction) that was mostly bone- and/or skin-involved.[80] Thalidomide was evaluated in a phase II study including 12 children and four adults with LCH.[89] Among 10 patients with low-risk disease (involvement of skin, lungs, and lymph nodes), an ORR of 70% was observed (4 CRs, 3 PRs). All but one patient, who had low-risk disease, had skin involvement. Administration of this drug was associated with significant toxicity and should be

Discussion update in progress

Version 2.2025 © 2025 National Comprehensive Cancer Network© (NCCN©), All rights reserved. NCCN Guidelines® and this illustration may not be reproduced in any form without the express written permission of NCCN.

PLEASE NOTE that use of this NCCN Content is governed by the End-User License Agreement, and you MAY NOT distribute this Content or use it with any artificial intelligence model or tool.
Printed by Máximo López Chenlo on 5/4/2026 6:21:12 PM. Copyright © 2026 National Comprehensive Cancer Network, Inc. All Rights Reserved.

avoided in patients with critical organ involvement, for whom this drug was not effective. A case report also describes a CR from lenalidomide in an adult with relapsed/refractory multisystem LCH (involvement of skin, lungs, and lymph nodes).[90]

Follow-up

Imaging (FDG-PET/CT [preferred], CT/MRI) of involved sites to evaluate treatment response should be done after 2 to 3 cycles of systemic therapy and after completion of treatment. It should also be performed after completion of surgical curettage and after RT. LCH may relapse or reactivate following systemic therapy, which most commonly occurs in the first 2 years following treatment.[54] Development of AVP deficiency after treatment may be a sign of disease reactivation.[54] Follow-up assessment depends on extent of disease and organ involvement, and a complete list of recommendations for surveillance following treatment of LCH can be found in the algorithm (see *Langerhans Cell Histiocytosis: Follow-up* in the algorithm.

Treatment for Relapsed/Refractory Disease

In relapsed and refractory LCH, an alternate systemic therapy regimen other than the one used in the first line may be utilized. However, if DOR to the first-line regimen was >1 year, repeating the same treatment may also be considered.[21]

Erdheim-Chester Disease

ECD is a rare histiocytic neoplasm, with approximately 1500 cases having been reported worldwide as of 2020. An increase in detection of cases has been observed over time, potentially due to improved recognition of this disease through imaging and pathology.[15,24,91] ECD predominantly affects adults and is rarely observed in children, with a median age of approximately 45 years in the United States, and is more common in men than women.[15,24,91] Mixed ECD/LCH is fairly common, with LCH lesions reported in 20% of patients with ECD.[48]

Similar to LCH, ECD presentation can range from single system and asymptomatic disease to severe multisystem and life-threatening disease. Prognosis is predominantly influenced by specific organ involvement.[91] Bone involvement affects almost all patients with ECD, with lower extremity bone pain being an especially common initial presenting symptom. Cardiovascular involvement, including pericardial disease, is reported to occur in about half of all patients[92-94] and is associated with poor prognosis.[95] Other affected organs/systems include the lungs, endocrine system, skin, and kidneys.[24,96] Periarterial fibrosis of the thoracic and/or abdominal aorta, referred to as “coated aorta,” is also commonly observed.[91,93,95,97-100] Retroperitoneal involvement tends to be asymptomatic, but extension to the renal sinus or middle to distal ureters may result in hydronephrosis.[101-103] CNS involvement occurs in 15% to 55% of cases[24,91,104] and is associated with worse prognosis.[105] Some ECD-related CNS lesions cause intracranial vascular infiltration, putting these patients at risk of ischemic stroke. AVP deficiency is the most common endocrine disorder in ECD, affecting about 25% to 50% of patients.[3,91,106] Other commonly observed endocrine manifestations of ECD include hyperprolactinemia, hypogonadism, adrenal insufficiency, and hypothyroidism.[3,106] Exophthalmos is also fairly common in ECD, and xanthelasma of the eyelids and periorbital spaces is a common cutaneous manifestation of ECD.[1,91] Involvement of the facial bones and maxillary sinuses has also been seen.[97]

Two retrospective studies demonstrated that a concomitant myeloid neoplasm can occur in 3% to 10% of ECD[107,108]; the higher rate (10%) in one study is likely due to inclusion of patients with mixed LCH/ECD.[107] In one case series, median age of patients with ECD and

Discussion update in progress

Version 2.2025 © 2025 National Comprehensive Cancer Network© (NCCN©), All rights reserved. NCCN Guidelines® and this illustration may not be reproduced in any form without the express written permission of NCCN.

PLEASE NOTE that use of this NCCN Content is governed by the End-User License Agreement, and you MAY NOT distribute this Content or use it with any artificial intelligence model or tool.
Printed by Máximo López Chenlo on 5/4/2026 6:21:12 PM. Copyright © 2026 National Comprehensive Cancer Network, Inc. All Rights Reserved.

a concomitant myeloid neoplasm was 65.4 years and tended to affect more men than women (male:female ratio = 2:1).[109]

Diagnosis of ECD

The diagnosis of ECD is largely made based on characteristic clinical and radiographic abnormalities. H&P is part of the essential workup for ECD with special attention needed to the common sites of involvement: the long bones (bilateral and symmetric diaphyseal and metaphyseal osteosclerosis with subchondral sparing); orbits (retro-orbital mass with exophthalmos; zanthelasma); CNS (pituitary gland, posterior fossa); lungs (interstitial changes); vascular (periaortic infiltrate; pericardium, right atrium); retroperitoneal/perinephritic or "hairy kidney". The presence of hairy kidney is highly suggestive of ECD and is present in 50% to 68% of patients while periarterial infiltration involving the thoracic or abdominal aorta and other vessels is present in 56% to 85% of patients with ECD.[3] Laboratory tests should also be conducted, and, similar to LCH, should include CBC, blood chemistry, coagulation studies, TSH, free T4, morning urine and serum osmolality, morning serum cortisol with ACTH, prolactin, IGF-1, and FSH/LH with testosterone or estradiol. C-reactive protein should also be evaluated, as it is often elevated in patients with ECD.[3,24] Whole-body FDG-PET/CT scan, which should include distal extremities, is also recommended along with a tissue biopsy as part of the essential workup for ECD. Full-body (vertex-to-toes) FDG-PET/CT is preferred to bone scan, as it allows for evaluation of metadiaphyseal osteosclerosis of the knees as well as other organ involvement.[3,15] Bilateral, symmetric diaphyseal, and metaphyseal osteosclerosis of the long bones of lower extremities is a characteristic finding of ECD.[2,3,15,24] In fact, bilateral symmetrical osteosclerosis of the metadiaphyseal bones around the knees is very common (>95%) and is pathognomonic of ECD.[3]

Additional evaluation is based on symptoms or organ involvement. CT of the chest, abdomen, and pelvis with contrast, sinuses with contrast, high-resolution CT of the chest, or MRI with and without contrast of the brain, orbit, spin, and sella turcica with or without pituitary (if AVP deficiency is suspected) are encouraged. CNS involvement may be detected using brain MRI with gadolinium contrast, and common findings include cerebellar and brain stem hyperintensities, cerebral white matter enhancement, and thickening of the pituitary stalk.[3,24] "Coated aorta" may be detected with CT, and arterial lesions characterized by circumferential thickening may be observed.[3,24,91,102] "Hairy kidney" detected on abdominal CT is characteristic of ECD (rarely seen in RDD and not seen in LCH) due to diffuse bilateral infiltration leading to stellate pattern of perinephric soft tissue thickening.[3,102] Adrenal hypertrophy may be observed if the perirenal infiltration extends to the adrenal gland.[102] In ECD with pulmonary involvement, chest CT may demonstrate mediastinal infiltration, pleural thickening, pleural effusion, and other pulmonary parenchymal abnormalities.[3] PFTs, TTE (especially for suspected pulmonary ECD), renal artery and testicular US, as well as technetium-99m MDP bone scintigraphy are also useful under certain circumstances. Cardiac involvement can also be determined with echocardiography and/or cardiac MRI. Findings and radiographic abnormalities include pericardial thickening, pericardial effusion, and myocardial infiltration, which, if present, most often involve the right atrioventricular groove and right atrial wall.[3] Subspecialty consultations (eg, neurology, endocrinology, nephrology, urology) should be carried out as clinically indicated. As with LCH, dermatology and ophthalmology evaluations may be considered for management of toxicities associated with BRAF and MEK inhibitors.[11-13] The complete recommendations for evaluation of ECD are provided in the algorithm and are adapted from recommendations from an expert consensus group[15] (see *Erdheim-Chester Disease: Workup/Evaluation* in the algorithm.

Discussion update in progress

Version 2.2025 © 2025 National Comprehensive Cancer Network© (NCCN©), All rights reserved. NCCN Guidelines® and this illustration may not be reproduced in any form without the express written permission of NCCN.

PLEASE NOTE that use of this NCCN Content is governed by the End-User License Agreement, and you MAY NOT distribute this Content or use it with any artificial intelligence model or tool.
Printed by Máximo López Chenlo on 5/4/2026 6:21:12 PM. Copyright © 2026 National Comprehensive Cancer Network, Inc. All Rights Reserved.

A biopsy of tumor tissue is recommended for all patients, and a bone marrow biopsy should be considered in those with unexplained CBC abnormalities, such as sustained cytopenia or cytosis without explainable etiology, to rule out myeloid neoplasms. Differential diagnosis should include evaluation for IgG4-related disease, which has a clinical presentation similar to that for ECD.[24] If ECD is present, the biopsy will show foamy histiocytes and Touton giant cells; however, this may be obscured by fibrosis or lymphoplasmacytic infiltrate.[110] IHC analysis should also be performed and include, at a minimum, evaluation of: CD68 or CD163+, S100, factor XIIa, and CD1a. *BRAF* V600E (VE1) IHC is also recommended. Allele-specific PCR for *BRAF* V600E mutations can be the first step if VE1 is not available. Further molecular testing, including NGS of fresh or paraffin-embedded tumor tissue, should also be performed and cover the common MAPK pathway mutations (*BRAF*, *ARAF*, *NRAS*, *KRAS*, *MAP2K1/2*) and other related pathway mutations (eg, *PIK3CA*, *CSF1R*). Gene fusion assays using an RNA-based molecular panel is also recommended and should cover *BRAF*, *ALK*, *RET*, and *NTRK1* rearrangements. If clinically indicated in cases without the usual MAPK pathway mutations, FISH for *BRAF*, *ALK*, *RET*, or *NTRK1* fusions may be performed. If there is a clinical concern for ALK rearrangement or if fusion panel testing is not available, ALK IHC and FISH studies can be performed. Molecular testing for somatic mutations and fusions should be conducted in a stepwise manner or in parallel, depending on clinical need and institutional protocols. The frequency of suspected molecular lesions should drive the order of testing if a stepwise algorithm is chosen. Mutational analysis of the peripheral blood is also an option if a biopsy is not possible due to location or risk factors.[110] Peripheral blood testing may be informative in multisystem disease. Determination of these molecular alterations should be performed, where available, as this aids both in the diagnosis of ECD and treatment decision-making.[15] For more information, see *Pathologic Analysis of Histiocytic Disorders* and *Histopathologic Characterization of ECD* in this Discussion.

Histopathologic Characterization of ECD

On H&E stain, ECD tumor tissue often demonstrates foamy mononucleated histiocytes with a small nucleus and an inconspicuous nucleoli, surrounding fibrosis, xanthogranulomatosis, and Touton giant cells.[2,3,15,24] Additionally, the cytoplasm is classically abundant, amorphous, and lipid-laden. Inflammatory cells, including reactive lymphocytes, neutrophils, and plasma cells are the common background cells with eosinophils being rare. Dense fibrosis may also be observed.[15] On IHC, neoplastic histiocytes are typically CD68-positive, CD163-positive, CD14-positive, factor XIIIa-positive, CD1a-negative, and CD207 (Langerin)-negative.[2,24,91] Typical features of the stroma as well as the histiocytic and reactive infiltrate have been found to vary depending on disease location (ie, bone, central nervous system [CNS], lung, skin, orbit, retroperitoneum, cardiac tissue).[111] CD1a-positive, S100-positive, and Langerin-positive findings can help distinguish LCH from ECD.[1,91] The possible presence of S100-positive cells with emperipolesis may lead to challenges in distinguishing ECD from RDD.[1 15]

Somatic mutations contributing to ECD partially overlap with that of LCH.[2] *BRAF* V600E activating mutations are present in 38% to 68% of ECD cases.[6,7,91,97,110,111] Other prevalent gene mutations in ECD include *MAP2K1/2, ARAF*, *NRAS*, *KRAS,* and *PIK3CA*.[7,8,110,111] *PIK3CA* activating mutations are more common in ECD than LCH. Moreover, *CSF1R* mutations and *BRAF, ALK*, and *NTRK1* fusions are found in a small number of ECD cases.[8,53,110] ECD co-occurring with RDD is most commonly driven by mutations in *MAP2K1/2*.[111,112] Extracutaneous or disseminated juvenile xanthogranuloma with mutations in the *MAPK* pathway has similar histopathology and phenotype to ECD and thus

Discussion update in progress

Version 2.2025 © 2025 National Comprehensive Cancer Network© (NCCN©), All rights reserved. NCCN Guidelines® and this illustration may not be reproduced in any form without the express written permission of NCCN.

PLEASE NOTE that use of this NCCN Content is governed by the End-User License Agreement, and you MAY NOT distribute this Content or use it with any artificial intelligence model or tool.
Printed by Máximo López Chenlo on 5/4/2026 6:21:12 PM. Copyright © 2026 National Comprehensive Cancer Network, Inc. All Rights Reserved.

may be considered ECD.[1] *BRAF* V600E (VE1) should be evaluated using IHC, but allele-specific PCR for *BRAF* V600E may be considered; see *Histopathologic Characterization of LCH* above. As with LCH, panel testing should include other mutations in the MAPK and other related pathways. For complete recommendations regarding pathologic analysis of ECD cases, see the *Principles of Pathology* in the algorithm.

Treatment of ECD

Treatment of ECD mainly consists of systemic therapy, though observation may be considered for patients with asymptomatic disease not involving critical organs such as the heart, brain, and CNS.

Preferred regimens for ECD in the first- or subsequent-line setting include vemurafenib for *BRAF* V600E-mutated disease and cobimetinib for patients with other MAP kinase pathway mutations, no other detectable/actionable mutation present, or if testing is not available. As discussed in the previous section covering targeted therapy in LCH, the phase II VE-BASKET study showed that vemurafenib is highly effective in patients with *BRAF* V600E-mutated ECD that is associated with near universal responses.[67] Results from the VE-BASKET study led to the U.S. Food and Drug Administration (FDA) approval of vemurafenib for treatment of ECD. However, the FDA-approved dose (960 mg twice daily) is associated with significant toxicity that very often results in discontinuation, dose interruption, or dose modification.[67] A retrospective study carried out at an NCCN Member Institution including 23 patients with *BRAF* V600E-mutated ECD showed that progressive disease did not occur in patients (n = 14) who received vemurafenib administered at half the FDA-approved dose (ie, 480 mg twice daily), though half of these patients still required further dose reduction, with 29% discontinuing vemurafenib treatment due to adverse events.[113] Additionally, the MEK inhibitor, cobimetinib, demonstrated efficacy in ECD in the phase II study by Diamond et al[12] discussed previously where 18 patients (12 of which had ECD) demonstrated consistent and durable responses when treated with this drug (see *Systemic Therapy for LCH* above for more information about this trial).

Other recommended regimens for patients with ECD include dabrafenib for *BRAF* V600E mutated disease and trametinib for MAP kinase pathway mutation or no other detectable/actionable mutation. Irrespective of mutation, cladribine, pegylated interferon alpha-2a and alpha-2b, sirolimus plus prednisone, oral methotrexate, or anakinra may also be used. The efficacy of dabrafenib for *BRAF* V600E-mutated ECD is supported by a retrospective single-center French study[114] and a multicenter case series.[115] As with LCH, dabrafenib appears to be less toxic than vemurafenib.[115] As described above for LCH (see *Systemic Therapy for LCH*), in a phase II trial in which 67% of patients were diagnosed with ECD, a 72% CR rate was demonstrated for cobimetinib.[12] These promising results were not limited to patients with a mutation in the MAPK pathway. A small study supports use of the MEK inhibitor trametinib for treatment of non-LCH histiocytic neoplasms, regardless of molecular profile.[116]

Prior to the availability of targeted therapy for ECD, the largest body of evidence supported the use of interferon alpha-2a and pegylated interferon alpha for the treatment of ECD.[91] In a multicenter, prospective, nonrandomized study conducted in Europe (N = 53), interferon alpha or pegylated interferon alpha treatment was associated with improved survival (HR, 0.32; 95% CI, 0.14–0.70; P = .006).[105] A single-center report from France (N = 8) showed that interferon alpha was most effective for relieving exophthalmos, bilateral hydronephrosis, and xanthelasma related to ECD, and was associated with a decrease in C-reactive protein.[117] This report cautioned against the use of interferon alpha in patients with ECD involving the CNS and/or cardiovascular system. However, a later single-center study from

Discussion update in progress

Version 2.2025 © 2025 National Comprehensive Cancer Network© (NCCN©), All rights reserved. NCCN Guidelines® and this illustration may not be reproduced in any form without the express written permission of NCCN.

PLEASE NOTE that use of this NCCN Content is governed by the End-User License Agreement, and you MAY NOT distribute this Content or use it with any artificial intelligence model or tool.
Printed by Máximo López Chenlo on 5/4/2026 6:21:12 PM. Copyright © 2026 National Comprehensive Cancer Network, Inc. All Rights Reserved.

France reported outcomes for a larger cohort (N = 24) that showed high-dose interferon alpha was associated with a clinical and/or radiologic improvement in 46% of patients, including those with severe ECD with CNS or cardiovascular involvement.[118] Interferon alpha as a treatment option for ECD is also supported by several case reports.[119,120] Interferon alpha has been discontinued in the United States and is therefore not recommended in the NCCN Guidelines. Pegylated interferon alpha, which has a more favorable toxicity profile compared to interferon alpha, is recommended as a substitute based on the evidence discussed above. Peginterferon alfa-2a is the only peginterferon alfa available for clinical use in the United States, and it may be substituted for peginterferon alfa-2b.[121-123]

Evidence supporting other systemic therapy options for treatment of ECD is primarily based on retrospective single-center studies and case series. A retrospective study conducted at an NCCN Member Institution evaluated the efficacy of cladribine as first- or subsequent-line treatment of ECD (n = 21).[124] The clinical ORR was 52%, with CR and PR observed in 4% and 46% of patients, respectively. Progressive disease was observed in 30% of patients. The response was durable, with the median DOR of 9 months in the responders. Toxicities associated with cladribine were relatively minimal. In a single-center study from Italy including 10 patients with ECD, sirolimus combined with prednisone was associated with an ORR of 60% (all PRs).[125] Oral methotrexate as first- or subsequent-line treatment of ECD was evaluated in a retrospective study conducted at an NCCN Member Institution (N = 13).[126] Oral methotrexate was administered either alone or in combination with prednisone or infliximab and was associated with a clinical ORR of 23% (all PRs). Progressive disease occurred in 70%. Despite the low ORR, methotrexate-based treatment was well-tolerated, and response was durable in some of those who responded to the treatment, especially those with ocular ECD. Finally, two small single-center studies showed good efficacy with the IL-1 receptor antagonist anakinra as a treatment option for ECD.[127,128]

As with LCH, other targeted therapies can also be selected for patients with ECD based on the respective molecular alteration. Crizotinib, alectinib, brigatinib, ceritinib, and lorlatinib are options for patients with *ALK* rearrangements while selpercatinib is recommended for ECD with rearrangements in *RET*.[53,129] Pexidartinib for ECD with activating mutations in *CSF1R*, and larotrectinib, entrectinib, repotrectinib for ECD with *NTRK* fusions, are all reasonable systemic therapy options when clinically indicated.[53,83-86,130] Since mutations in *PIK3CA* are fairly common in ECD[7], mTOR inhibitors such as sirolimus and everolimus should also be considered when clinically indicated.[87] Of note, lower doses are to be considered upon starting targeted agents.

Follow-up

Similar to LCH, follow-up assessment for patients with ECD depends on extent of disease and organ involvement. FDG-PET/CT should be used to monitor disease response once treatment is initiated. Organ-specific cross-sectional imaging (CT or MRI) should also be utilized, and ongoing evaluation for pituitary hormone abnormalities should be incorporated. Regular skin examination and ECG is recommended for patients treated with *BRAF* inhibitors with regular skin and retinal examination and ECG also being recommended for patients treated with MEK inhibitors. For further information, see *Follow-up for ECD* in the algorithm.

Rosai-Dorfman Disease

RDD is another rare histiocytic disorder that mainly affects children but is also diagnosed in adults. In RDD, accumulation of abnormal histiocytes in lymph node sinuses, lymphatic vessels of internal organs, and other extranodal sites is observed. Previously RDD was considered

Discussion update in progress

Version 2.2025 © 2025 National Comprehensive Cancer Network© (NCCN©), All rights reserved. NCCN Guidelines® and this illustration may not be reproduced in any form without the express written permission of NCCN.

PLEASE NOTE that use of this NCCN Content is governed by the End-User License Agreement, and you MAY NOT distribute this Content or use it with any artificial intelligence model or tool.
Printed by Máximo López Chenlo on 5/4/2026 6:21:12 PM. Copyright © 2026 National Comprehensive Cancer Network, Inc. All Rights Reserved.

a benign and self-limiting condition; however, more recent data has contributed to RDD being officially recognized as a blood cancer by the World Health Organization (WHO) in 2022.[131] This disease is more common in men than in women and often affects individuals of African ancestry.[24,132] Cause is unknown but may be associated with familial, autoimmune, and/or malignant processes. It is a heterogeneous condition with a presentation that may be classified as single or regional lymph node-involved or localized to the skin and other organs. Prognosis is generally very good but becomes worse as the number of involved nodal groups increases.[132] Recurrent disease is reported to occur in about one in three patients with RDD.[133]

Extranodal involvement occurs often in RDD, with common sites of involvement including the skin, soft tissue, upper respiratory tract, multifocal bone (mostly osteolytic lesions), retroperitoneum, and eye/retro-orbital tissue with lymphadenopathy.[3,132,133] Bilateral massive cervical lymphadenopathy also commonly occurs and is often painless, though involvement of the mediastinal, inguinal, and axillary lymph nodes may also occur.[132] Skin-involved RDD often presents as subcutaneous masses and, less often, as cutaneous lesions.[133] Involvement of the nasal cavity, paranasal sinuses, and parotid gland have also been reported.[24,132,134] CNS involvement may also occur but is generally rare.[132,133,135,136] CNS-involved RDD may mimic meningioma.[132]

RDD may co-occur with Hodgkin and non-Hodgkin lymphoma, other histiocytic disorders, cutaneous clear-cell sarcoma, and following myelodysplastic syndrome and allogeneic stem transplant for precursor B-cell acute lymphoblastic leukemia.[24,132,133] Germline mutations in *SLC29A3*, which is associated with Faisalabad histiocytosis, H syndrome, and pigmented hypertrichotic dermatosis with insulin-dependent diabetes, have been found in cases of familial RDD.[132] About 20% of patients with H syndrome have RDD.[137] Germline mutation in the *FAS* gene *TNFRSF*, which is associated with autoimmune lymphoproliferative syndrome (ALPS) type I, has also been found in RDD cases.[132] Immunologic diseases associated with RDD include systemic lupus erythematous, idiopathic juvenile arthritis, and autoimmune hemolytic anemia.[132]

Diagnosis of RDD

Diagnosis of RDD involves a clinical and radiologic examination, as well as histopathologic analysis. Essential workup for RDD includes a comprehensive H&P with special attention to the common sites of involvement: peripheral lymphadenopathy, subcutaneous nodules, and extranodal sites (skin [HEENT], soft tissue, upper respiratory tract, bone, retroperitoneum, orbits, and spleen). Evaluation of the endocrine system and any intrathoracic/pulmonary, cardiovascular, gastrointestinal, musculoskeletal genital, renal, and cutaneous symptoms is recommended. Neurologic and psychological assessments are also encouraged as needed. History of inherited conditions predisposing to RDD (eg, ALPS), malignancies and other neoplasia associated with RDD (eg, Hodgkin and non-Hodgkin lymphoma, other histiocytic disorders), and other autoimmune disorders (eg, systemic lupus erythematous, idiopathic juvenile arthritis) should be evaluated based on clinical symptoms and family history. Family history should also be considered if parents are consanguineous, possess an autoimmune disease, or are of Turkish/Pakistani or Middle Eastern ancestry.

Full-body FDG-PET/CT is also recommended as part of the baseline evaluation of RDD. A single-center retrospective study including 109 FDG-PET/CT scans in 27 patients with RDD showed that PET/CT detected lesions not recognized by anatomic cross-sectional imaging in 30% of patients with available prior CT or MRI (n = 20).[138] Results of

Discussion update in progress

Version 2.2025 © 2025 National Comprehensive Cancer Network© (NCCN©), All rights reserved. NCCN Guidelines® and this illustration may not be reproduced in any form without the express written permission of NCCN.

PLEASE NOTE that use of this NCCN Content is governed by the End-User License Agreement, and you MAY NOT distribute this Content or use it with any artificial intelligence model or tool.
Printed by Máximo López Chenlo on 5/4/2026 6:21:12 PM. Copyright © 2026 National Comprehensive Cancer Network, Inc. All Rights Reserved.

PET/CT scans also led to changes in treatment in 41% of patients. Cross-sectional imaging can reveal dermatologic involvement in the form of lobular soft-tissue lesions in the subcutaneous space.[3] Pulmonary involvement in RDD tends to manifest as mediastinal lymphadenopathy, airway disease, pleural effusion, and cystic and interstitial lung disease.[139] Extranodal retroperitoneal involvement, if present, would appear in radiologic findings as wispy infiltration and/or renal hilar masses.[3] MRI of the head tends to be superior for evaluation of the sinuses and orbits, compared to PET/CT.[3] MRI of the brain and spine is useful for identification of asymptomatic neurologic involvement.[132] Based on symptoms and organ involvement, further imaging of the chest, abdomen, and pelvis as well as the sinuses with a CT scan can be performed as well as imaging of the brain, orbit, spine, and sella turcica with or without pituitary evaluation in the event of AVP deficiency using MRI. Imaging studies should be performed with contrast unless contrast is contraindicated. PFTs and TTE may be needed in the event of pulmonary RDD. Thyroid and testicular US can also be performed if clinically indicated. Like LCH and ECD, dermatology and ophthalmology evaluations should be considered in appropriate patients due to toxicities associated with BRAF and MEK inhibitors.[11-13] The complete recommendations for evaluation of RDD are provided in the algorithm and are adapted from recommendations from an expert consensus group[132] (see *Rosai-Dorfman Disease: Workup/Evaluation* in the algorithm.

Additionally, laboratory evaluation should be included in the essential workup with CBC, comprehensive metabolic panel, coagulation studies, and an evaluation of C-reactive protein, uric acid, LDH, and serum immunoglobulins being recommended.[132] If autoimmune disease is suspected based on clinical examination, then laboratory evaluation should also include antinuclear antigen, antineutrophil cytoplasmic antibodies, rheumatoid factor, and HLA-B27. The ALPS panel is clinically indicated in patients with autoimmunity and lymphadenopathy. Laboratory evaluation in patients with anemia should include a Coombs test, haptoglobin, reticulocyte count, and blood smear. Lumbar puncture should be carried out if there are brain lesions that cannot be biopsied due to location. If a patient has an unexplained, abnormal CBC, bone marrow aspirate and biopsy are recommended.[132] As with LCH and ECD, biopsy of tumor tissue is recommended for diagnosis and molecular testing (both IHC and NGS).[110] If biopsy is not feasible, then peripheral blood analysis is reasonable. The minimum IHC panel performed should include: CD68 or CD163, S100, CD1a, and cyclin D1; however, caution should be applied to cyclin D1 as it could also be detected in concurrent lymphocytic or histiocytic neoplasm. *BRAF* V600E (VE1) IHC should also be included in the analysis. NGS of tumor tissue should evaluate mutations in the MAPK pathway and other related pathways. Gene fusion assays should also be performed while germline mutation testing is optional in these patients. For more information, see *Pathologic Analysis of Histiocytic Disorders* and *Histopathologic Characterization of RDD* in this Discussion.

Histopathologic Characterization of RDD

Compared to LCH and ECD, histopathologic analysis of RDD can be challenging, as RDD tissue tends to contain relatively few lesional cells.[133] Large histiocytic cells with round and hypochromatic nuclei, distinct and central nucleoli, and an abundant amount of pale cytoplasm are required for diagnosis or RDD.[1] Emperipolesis, specifically intracytoplasmic leukocytes, is a frequently observed feature of RDD.[1-3,24,132,133] However, emperipolesis may be observed less often in extranodal lesion tissue.[132] Abundant plasma cells in the medullary cords and around the venules is a hallmark of nodal RDD along with polyclonal IgG4.[15,132] Other pathologic hallmarks include the accumulation of CD68-positive, CD163-positive, CD14-positive, and S100-positive histiocytic cells.[1-3,132,133] RDD histiocytes tend to be CD1a-

Discussion update in progress

Version 2.2025 © 2025 National Comprehensive Cancer Network© (NCCN©), All rights reserved. NCCN Guidelines® and this illustration may not be reproduced in any form without the express written permission of NCCN.

PLEASE NOTE that use of this NCCN Content is governed by the End-User License Agreement, and you MAY NOT distribute this Content or use it with any artificial intelligence model or tool.
Printed by Máximo López Chenlo on 5/4/2026 6:21:12 PM. Copyright © 2026 National Comprehensive Cancer Network, Inc. All Rights Reserved.

and CD207-negative, which helps to distinguish from LCH.[132] Cyclin D1 expression by the abnormal histiocytes, OCT2-positivity, and increased IgG4-positive plasma cells in the background inflammatory infiltrate, may also be found.[140,141] OCT2 IHC was found in a recent study to potentially be helpful in select cases to confirm a suspected diagnosis of RDD along with other common diagnostic markers.[142]

Unlike LCH and ECD, *BRAF* V600E activating mutations are not commonly observed in patients with RDD.[3,24,132] However, *KRAS*, *MAP21K, ARAF*, and *NRAS* mutations have been found in patients with RDD.[8,132,133,143] As with LCH and ECD, NGS panel testing should evaluate mutations in the MAPK pathway as well as other related pathways. Even though some of these mutations (eg, *BRAF* V600E) are less common in RDD, a comprehensive panel test is helpful for distinguishing RDD from other histiocytic neoplasms. Germline testing for *SLC29A3*, if familial RDD is suspected, and *TNFRSF* should also be considered if clinically indicated. Complete recommendations regarding pathologic analysis of RDD cases can be found in the *Principles of Pathology* in the algorithm.

Treatment of RDD

Observation is a reasonable treatment strategy for patients with asymptomatic and mild RDD, as spontaneous remission has been reported to occur in 40% of these patients.[132,133] Surgical resection is also a reasonable curative option for those with isolated disease or for the debulking of symptomatic disease of the CNS, sinuses, or airways.[132,133] Patients with extranodal disease impacting critical organs and those with serious RDD-related complications require treatment with systemic therapies (see below). RT should only be used for palliative purposes in patients with multifocal symptomatic disease.[132] Case reports have shown some efficacy for RT when used to treat refractory disease in the eyelid and soft tissue of the cheek,[144] as well as RDD lesions causing airway obstruction.[145] RT dosing for RDD is not well-established, but 30 to 50 Gy may be used.[132,145]

Systemic Therapy

Systemic therapy is recommended for first-line treatment of symptomatic unresectable or multifocal disease and for treatment of relapsed/refractory disease. There is a dearth of research in this area, and some systemic therapy options that may be used for treating RDD are extrapolated from ECD.[133] Preferred regimens for the treatment of RDD include cobimetinib for patients with MAP kinase pathway mutation, no other detectable/actionable mutation, or if testing is not available. Cladribine, cytarabine, oral methotrexate, and prednisone or other corticosteroids are also preferred regimens irrespective of mutation.

Cobimetinib was evaluated in a study of 16 patients with RDD, the largest reported series of patients with RDD to date, 50% of whom had either detectable *KRAS* or *MEK* somatic alterations. Positive outcomes were observed with cobimetinib in this cohort, most notably in those with demonstrated *KRAS*- or *MEK*-variant RDD.[146] Patients with genetic alterations in *KRAS* or *MEK* had a significantly enhanced ORR (88% vs. 38%) and PFS at 1 year (100% vs. 29%) as well as deeper responses (71% complete responses vs. 0%) compared to those without these alterations.[146]

A retrospective study, conducted at Mayo Clinic (N = 57), revealed that corticosteroid treatment (most often prednisone) was associated with a 56% ORR in the first-line setting, with relapse occurring in 53% of patients, and a 67% ORR in the subsequent-line setting.[133] This study also showed that cladribine was the most commonly used systemic therapy for treatment of recurrent disease and was associated with a 67% ORR.[133,147] Case reports support use of cytarabine and oral methotrexate for treatment of RDD.[148-151] A case report describing

Discussion update in progress

Version 2.2025 © 2025 National Comprehensive Cancer Network© (NCCN©), All rights reserved. NCCN Guidelines® and this illustration may not be reproduced in any form without the express written permission of NCCN.

PLEASE NOTE that use of this NCCN Content is governed by the End-User License Agreement, and you MAY NOT distribute this Content or use it with any artificial intelligence model or tool.
Printed by Máximo López Chenlo on 5/4/2026 6:21:12 PM. Copyright © 2026 National Comprehensive Cancer Network, Inc. All Rights Reserved.

treatment of a pediatric patient with RDD supports use of methotrexate delivered intravenously,[152] although oral administration is generally used.[153,154] Steroids may be used to treat patients with symptomatic nodal or cutaneous disease, for unresectable or multifocal extranodal disease, and/or for relief of symptoms from CNS- or orbit-involved disease.[132,133] As described above, the Mayo Clinic study supports use of prednisone for treatment of RDD, both in the first- and subsequent-line settings.[133] This study showed that prednisone combined with 6-mercaptopurine and either methotrexate or azathioprine was also associated with disease response in the subsequent-line setting in patients with subcutaneous and lymph node involvement, and a PR was achieved in one patient who was treated with cyclophosphamide, vincristine, and prednisone.

Other recommended regimens include trametinib for MAP kinase pathway mutation, no other detectable/actionable mutation, or if testing is not available, or vinblastine plus prednisone, IV or SC methotrexate, or lenalidomide, irrespective of mutation. Evidence supporting use of targeted agents for RDD is evolving, particularly for MEK inhibitors, and some options may be used based on extrapolation of evidence for use in ECD and LCH. The MEK inhibitor trametinib is an option, regardless of molecular profile, including in those without *BRAF* V600E mutations.[116,155]

Prednisone combined with vinblastine is also supported by a case report describing treatment of a pediatric patient with RDD,[156] but this regimen is associated with increased risk of neuropathy in adults.[77] Optimal duration of steroid treatment is unknown at this time; treating to optimal response, followed by a slow taper, is a reasonable strategy.[132] Adverse effects from steroids should be carefully monitored, though these are generally well-tolerated.[133] Additionally, two case studies demonstrated that lenalidomide was potentially effective in treating patients with RDD that had received previous therapy.[157,158]

Just as with LCH and ECD, targeted systemic therapy options may be recommended in certain circumstances.[53,83-85] These include: crizotinib for *ALK* rearrangements, selpercatinib for *RET* rearrangements, pexidartinib for activating mutations in *CSF1R*, larotrectinib, repotrectinib, and entrectinib for *NTRK* fusions, everolimus for PIK3CA mutations, and sirolimus for those associated with ALPS and/ or PIK3CA mutation.[53,83-86,159] Rituximab and thalidomide may also be useful irrespective of mutation for IgG4-related nodal and immune-cytopenia disease or for cutaneous involvement, respectively.[151,160] For more information on systemic therapy options for RDD treatment, see HIST-D 4 of 6 *Principles of Systemic Therapy for RDD* in the algorithm.

Follow-up

As with LCH and ECD, follow-up assessment for patients with RDD depends on extent of disease and organ involvement and includes post-treatment surveillance and imaging of involved sites. A complete list of recommendations for surveillance following treatment of RDD can be found in the algorithm (see *Rosai-Dorfman Disease: Follow-up* in the algorithm).

Supportive Care for Patients

The management of histiocytic neoplasms, as well as the disorders themselves, can lead to various toxicities and chronic symptoms.[15,33,161,162] BRAF and MEK Inhibitors are not always tolerated at the full doses that are approved for melanoma. Therefore, for patients without CNS involvement it may be reasonable to start at half the approved dose and then modify the dose over time based on tolerance and toxicities. These drugs can lead to cutaneous toxicities, such as the acneiform rash that can occur with MEK inhibitors. In addition, there is

Discussion update in progress

Version 2.2025 © 2025 National Comprehensive Cancer Network© (NCCN©), All rights reserved. NCCN Guidelines® and this illustration may not be reproduced in any form without the express written permission of NCCN.

PLEASE NOTE that use of this NCCN Content is governed by the End-User License Agreement, and you MAY NOT distribute this Content or use it with any artificial intelligence model or tool.
Printed by Máximo López Chenlo on 5/4/2026 6:21:12 PM. Copyright © 2026 National Comprehensive Cancer Network, Inc. All Rights Reserved.

an increased risk of cutaneous squamous cell carcinoma with BRAF inhibitor use. Therefore, routine dermatologic examination is recommended. Tyrosine kinase inhibitors may also be poorly tolerated at full doses, and it may be reasonable to start with one or two dose reductions and then adjust the dose based on response.

Separate from drug toxicities, patients often have other quality of life issues related to chronic pain, fatigue, depression, and anxiety. Patients with histiocytic disorders (especially ECD and LDH) often struggle with chronic generalized pain and fatigue that is out of proportion to the disease involvement. The oral stimulant methylphenidate can be used and appears safe for the long-term use in patients with cases of severe fatigue. Many of these patients also fit the criteria for myalgic encephalomyelitis/chronic fatigue syndrome. Also, some patients have residual pain at the site of a tumor bed despite complete resection (especially in the case of bone lesions from LCH) and much of the chronic pain may not respond well to available analgesics. There is a high prevalence of depression and anxiety that compounds these symptoms further. All of which can worsen the health-related quality of life of these patients significantly. It is important for clinicians to acknowledge these symptoms fully and refer the patients to appropriate supportive care services. Depending on the specific manifestations of their disease, patients should also continue to closely follow up with their pulmonary/neurology/endocrinology specialist during surveillance.

Summary

The NCCN Guidelines for Histiocytic Neoplasms provide an evidence- and consensus-based approach for the diagnosis and treatment of adult histiocytic neoplasms, which are relatively rare heterogeneous hematologic disorders. LCH, ECD, and RDD are the most common, but these diseases, given their rarity, overlap, and co-occurrence with other types of neoplasms, pose a diagnostic challenge. Appropriate diagnosis is necessary to achieve the best clinical outcomes with immunophenotyping and molecular marker profiling being critical components to differential diagnosis. Additionally, molecular testing provides guidance on the most effective systemic therapy options with many patients having complete recoveries. Research continues to improve therapeutic approaches, especially to in the context of targeting abnormal cells while simultaneously sparing normal tissue, and the NCCN Panel continues to encourage patients to participate in well-designed clinical trials in order to enable future advancement for management of these diseases.

Discussion update in progress

Version 2.2025 © 2025 National Comprehensive Cancer Network© (NCCN©), All rights reserved. NCCN Guidelines® and this illustration may not be reproduced in any form without the express written permission of NCCN.

PLEASE NOTE that use of this NCCN Content is governed by the End-User License Agreement, and you MAY NOT distribute this Content or use it with any artificial intelligence model or tool.
Printed by Máximo López Chenlo on 5/4/2026 6:21:12 PM. Copyright © 2026 National Comprehensive Cancer Network, Inc. All Rights Reserved.

References

1. Emile JF, Abla O, Fraitag S, et al. Revised classification of histiocytoses and neoplasms of the macrophage-dendritic cell lineages. Blood 2016;127:2672-2681. Available at: https://www.ncbi.nlm.nih.gov/pubmed/26966089.

2. Durham BH. Molecular characterization of the histiocytoses: Neoplasia of dendritic cells and macrophages. Semin Cell Dev Biol 2019;86:62-76. Available at: https://www.ncbi.nlm.nih.gov/pubmed/29526544.

3. Goyal G, Young JR, Koster MJ, et al. The Mayo Clinic Histiocytosis Working Group Consensus Statement for the Diagnosis and Evaluation of Adult Patients With Histiocytic Neoplasms: Erdheim-Chester Disease, Langerhans Cell Histiocytosis, and Rosai-Dorfman Disease. Mayo Clin Proc 2019;94:2054-2071. Available at: https://www.ncbi.nlm.nih.gov/pubmed/31472931.

4. Histiocytosis syndromes in children. Writing Group of the Histiocyte Society. Lancet 1987;1:208-209. Available at: https://www.ncbi.nlm.nih.gov/pubmed/2880029.

5. Badalian-Very G, Vergilio JA, Degar BA, et al. Recurrent BRAF mutations in Langerhans cell histiocytosis. Blood 2010;116:1919-1923. Available at: https://www.ncbi.nlm.nih.gov/pubmed/20519626.

6. Haroche J, Charlotte F, Arnaud L, et al. High prevalence of BRAF V600E mutations in Erdheim-Chester disease but not in other non-Langerhans cell histiocytoses. Blood 2012;120:2700-2703. Available at: https://www.ncbi.nlm.nih.gov/pubmed/22879539.

7. Emile JF, Diamond EL, Helias-Rodzewicz Z, et al. Recurrent RAS and PIK3CA mutations in Erdheim-Chester disease. Blood 2014;124:3016-3019. Available at: https://www.ncbi.nlm.nih.gov/pubmed/25150293.

8. Diamond EL, Durham BH, Haroche J, et al. Diverse and Targetable Kinase Alterations Drive Histiocytic Neoplasms. Cancer Discov 2016;6:154-165. Available at: https://www.ncbi.nlm.nih.gov/pubmed/26566875.

9. PubMed Overview. National Institutes of Health. . 2024. Available at: https://pubmed.ncbi.nlm.nih.gov/about/. Accessed 4/01/2024.

10. Freedman-Cass DA, Fischer T, Alpert AB, et al. The Value and Process of Inclusion: Using Sensitive, Respectful, and Inclusive Language and Images in NCCN Content. J Natl Compr Canc Netw 2023;21:434-441. Available at: https://www.ncbi.nlm.nih.gov/pubmed/37156485.

11. Lamiaux M, Scalbert C, Lepesant P, et al. Severe skin toxicity with organ damage under the combination of targeted therapy following immunotherapy in metastatic melanoma. Melanoma Res 2018;28:451-457. Available at: https://www.ncbi.nlm.nih.gov/pubmed/29985833.

12. Diamond EL, Durham BH, Ulaner GA, et al. Efficacy of MEK inhibition in patients with histiocytic neoplasms. Nature 2019;567:521-524. Available at: https://www.ncbi.nlm.nih.gov/pubmed/30867592.

13. Urner-Bloch U, Urner M, Jaberg-Bentele N, et al. MEK inhibitor-associated retinopathy (MEKAR) in metastatic melanoma: Long-term ophthalmic effects. Eur J Cancer 2016;65:130-138. Available at: https://www.ncbi.nlm.nih.gov/pubmed/27497344.

14. Chang KTE, Tay AZE, Kuick CH, et al. ALK-positive histiocytosis: an expanded clinicopathologic spectrum and frequent presence of KIF5B-ALK fusion. Mod Pathol 2019;32:598-608. Available at: https://www.ncbi.nlm.nih.gov/pubmed/30573850.

15. Goyal G, Heaney ML, Collin M, et al. Erdheim-Chester disease: consensus recommendations for evaluation, diagnosis, and treatment in the molecular era. Blood 2020;135:1929-1945. Available at: https://www.ncbi.nlm.nih.gov/pubmed/32187362.

16. Guyot-Goubin A, Donadieu J, Barkaoui M, et al. Descriptive epidemiology of childhood Langerhans cell histiocytosis in France,

Discussion update in progress

Version 2.2025 © 2025 National Comprehensive Cancer Network© (NCCN©), All rights reserved. NCCN Guidelines® and this illustration may not be reproduced in any form without the express written permission of NCCN.

PLEASE NOTE that use of this NCCN Content is governed by the End-User License Agreement, and you MAY NOT distribute this Content or use it with any artificial intelligence model or tool.
Printed by Máximo López Chenlo on 5/4/2026 6:21:12 PM. Copyright © 2026 National Comprehensive Cancer Network, Inc. All Rights Reserved.

2000-2004. Pediatr Blood Cancer 2008;51:71-75. Available at: https://www.ncbi.nlm.nih.gov/pubmed/18260117.

17. Stalemark H, Laurencikas E, Karis J, et al. Incidence of Langerhans cell histiocytosis in children: a population-based study. Pediatr Blood Cancer 2008;51:76-81. Available at: https://www.ncbi.nlm.nih.gov/pubmed/18266220.

18. Goyal G, Shah MV, Hook CC, et al. Adult disseminated Langerhans cell histiocytosis: incidence, racial disparities and long-term outcomes. Br J Haematol 2018;182:579-581. Available at: https://www.ncbi.nlm.nih.gov/pubmed/28653448.

19. Goyal G, Acosta-Medina AA, Abeykoon JP, et al. Long-term outcomes among adults with Langerhans cell histiocytosis. Blood Adv 2023;7:6568-6578. Available at: https://www.ncbi.nlm.nih.gov/pubmed/37698994.

20. Willman CL, Busque L, Griffith BB, et al. Langerhans'-cell histiocytosis (histiocytosis X)--a clonal proliferative disease. N Engl J Med 1994;331:154-160. Available at: https://www.ncbi.nlm.nih.gov/pubmed/8008029.

21. Girschikofsky M, Arico M, Castillo D, et al. Management of adult patients with Langerhans cell histiocytosis: recommendations from an expert panel on behalf of Euro-Histio-Net. Orphanet J Rare Dis 2013;8:72. Available at: https://www.ncbi.nlm.nih.gov/pubmed/23672541.

22. Allen CE, Merad M, McClain KL. Langerhans-Cell Histiocytosis. N Engl J Med 2018;379:856-868. Available at: https://www.ncbi.nlm.nih.gov/pubmed/30157397.

23. Swerdlow SH, Campo E, Pileri SA, et al. The 2016 revision of the World Health Organization classification of lymphoid neoplasms. Blood 2016;127:2375-2390. Available at: https://www.ncbi.nlm.nih.gov/pubmed/26980727.

24. Haroche J, Cohen-Aubart F, Rollins BJ, et al. Histiocytoses: emerging neoplasia behind inflammation. Lancet Oncol 2017;18:e113-e125. Available at: https://www.ncbi.nlm.nih.gov/pubmed/28214412.

25. Ma J, Laird JH, Chau KW, et al. Langerhans cell histiocytosis in adults is associated with a high prevalence of hematologic and solid malignancies. Cancer Med 2019;8:58-66. Available at: https://www.ncbi.nlm.nih.gov/pubmed/30597769.

26. Vassallo R, Ryu JH, Schroeder DR, et al. Clinical outcomes of pulmonary Langerhans'-cell histiocytosis in adults. N Engl J Med 2002;346:484-490. Available at: https://www.ncbi.nlm.nih.gov/pubmed/11844849.

27. Tazi A. Adult pulmonary Langerhans' cell histiocytosis. Eur Respir J 2006;27:1272-1285. Available at: https://www.ncbi.nlm.nih.gov/pubmed/16772390.

28. Makras P, Terpos E, Kanakis G, et al. Reduced bone mineral density in adult patients with Langerhans cell histiocytosis. Pediatr Blood Cancer 2012;58:819-822. Available at: https://www.ncbi.nlm.nih.gov/pubmed/21548013.

29. Rigaud C, Barkaoui MA, Thomas C, et al. Langerhans cell histiocytosis: therapeutic strategy and outcome in a 30-year nationwide cohort of 1478 patients under 18 years of age. Br J Haematol 2016;174:887-898. Available at: https://www.ncbi.nlm.nih.gov/pubmed/27273725.

30. Arico M, Girschikofsky M, Genereau T, et al. Langerhans cell histiocytosis in adults. Report from the International Registry of the Histiocyte Society. Eur J Cancer 2003;39:2341-2348. Available at: https://www.ncbi.nlm.nih.gov/pubmed/14556926.

31. Grois N, Fahrner B, Arceci RJ, et al. Central nervous system disease in Langerhans cell histiocytosis. J Pediatr 2010;156:873-881 e871. Available at: https://www.ncbi.nlm.nih.gov/pubmed/20434166.

Discussion update in progress

Version 2.2025 © 2025 National Comprehensive Cancer Network© (NCCN©), All rights reserved. NCCN Guidelines® and this illustration may not be reproduced in any form without the express written permission of NCCN.

PLEASE NOTE that use of this NCCN Content is governed by the End-User License Agreement, and you MAY NOT distribute this Content or use it with any artificial intelligence model or tool.
Printed by Máximo López Chenlo on 5/4/2026 6:21:12 PM. Copyright © 2026 National Comprehensive Cancer Network, Inc. All Rights Reserved.

32. Heritier S, Barkaoui MA, Miron J, et al. Incidence and risk factors for clinical neurodegenerative Langerhans cell histiocytosis: a longitudinal cohort study. Br J Haematol 2018;183:608-617. Available at: https://www.ncbi.nlm.nih.gov/pubmed/30421536.

33. Goyal G, Tazi A, Go RS, et al. International expert consensus recommendations for the diagnosis and treatment of Langerhans cell histiocytosis in adults. Blood 2022;139:2601-2621. Available at: https://www.ncbi.nlm.nih.gov/pubmed/35271698.

34. Phillips M, Allen C, Gerson P, McClain K. Comparison of FDG-PET scans to conventional radiography and bone scans in management of Langerhans cell histiocytosis. Pediatr Blood Cancer 2009;52:97-101. Available at: https://www.ncbi.nlm.nih.gov/pubmed/18951435.

35. Albano D, Bosio G, Giubbini R, Bertagna F. Role of (18)F-FDG PET/CT in patients affected by Langerhans cell histiocytosis. Jpn J Radiol 2017;35:574-583. Available at: https://www.ncbi.nlm.nih.gov/pubmed/28748503.

36. Obert J, Vercellino L, Van Der Gucht A, et al. (18)F-fluorodeoxyglucose positron emission tomography-computed tomography in the management of adult multisystem Langerhans cell histiocytosis. Eur J Nucl Med Mol Imaging 2017;44:598-610. Available at: https://www.ncbi.nlm.nih.gov/pubmed/27645693.

37. Thingujam B, Yu YT, Lee JY, et al. Tumour-stage mycosis fungoides initially misdiagnosed as Langerhans cell histiocytosis. Pathology 2020;52:593-596. Available at: https://www.ncbi.nlm.nih.gov/pubmed/32600661.

38. Collin M, Bigley V, McClain KL, Allen CE. Cell(s) of Origin of Langerhans Cell Histiocytosis. Hematol Oncol Clin North Am 2015;29:825-838. Available at: https://www.ncbi.nlm.nih.gov/pubmed/26461145.

39. Grois N, Prayer D, Prosch H, et al. Neuropathology of CNS disease in Langerhans cell histiocytosis. Brain 2005;128:829-838. Available at: https://www.ncbi.nlm.nih.gov/pubmed/15705614.

40. Chatterjee D, Vishwajeet V, Saikia UN, et al. CyclinD1 Is Useful to Differentiate Langerhans Cell Histiocytosis From Reactive Langerhans Cells. Am J Dermatopathol 2019;41:188-192. Available at: https://www.ncbi.nlm.nih.gov/pubmed/30124506.

41. Shanmugam V, Craig JW, Hornick JL, et al. Cyclin D1 Is Expressed in Neoplastic Cells of Langerhans Cell Histiocytosis but Not Reactive Langerhans Cell Proliferations. Am J Surg Pathol 2017;41:1390-1396. Available at: https://www.ncbi.nlm.nih.gov/pubmed/28622183.

42. Berres ML, Merad M, Allen CE. Progress in understanding the pathogenesis of Langerhans cell histiocytosis: back to Histiocytosis X? Br J Haematol 2015;169:3-13. Available at: https://www.ncbi.nlm.nih.gov/pubmed/25430560.

43. Rollins BJ. Genomic Alterations in Langerhans Cell Histiocytosis. Hematol Oncol Clin North Am 2015;29:839-851. Available at: https://www.ncbi.nlm.nih.gov/pubmed/26461146.

44. Berres ML, Lim KP, Peters T, et al. BRAF-V600E expression in precursor versus differentiated dendritic cells defines clinically distinct LCH risk groups. J Exp Med 2014;211:669-683. Available at: https://www.ncbi.nlm.nih.gov/pubmed/24638167.

45. Heritier S, Emile JF, Barkaoui MA, et al. BRAF Mutation Correlates With High-Risk Langerhans Cell Histiocytosis and Increased Resistance to First-Line Therapy. J Clin Oncol 2016;34:3023-3030. Available at: https://www.ncbi.nlm.nih.gov/pubmed/27382093.

46. Satoh T, Smith A, Sarde A, et al. B-RAF mutant alleles associated with Langerhans cell histiocytosis, a granulomatous pediatric disease. PLoS One 2012;7:e33891. Available at: https://www.ncbi.nlm.nih.gov/pubmed/22506009.

47. Brown NA, Furtado LV, Betz BL, et al. High prevalence of somatic MAP2K1 mutations in BRAF V600E-negative Langerhans cell histiocytosis. Blood 2014;124:1655-1658. Available at: https://www.ncbi.nlm.nih.gov/pubmed/24982505.

Discussion update in progress

Version 2.2025 © 2025 National Comprehensive Cancer Network© (NCCN©), All rights reserved. NCCN Guidelines® and this illustration may not be reproduced in any form without the express written permission of NCCN.

PLEASE NOTE that use of this NCCN Content is governed by the End-User License Agreement, and you MAY NOT distribute this Content or use it with any artificial intelligence model or tool.
Printed by Máximo López Chenlo on 5/4/2026 6:21:12 PM. Copyright © 2026 National Comprehensive Cancer Network, Inc. All Rights Reserved.

48. Hervier B, Haroche J, Arnaud L, et al. Association of both Langerhans cell histiocytosis and Erdheim-Chester disease linked to the BRAFV600E mutation. Blood 2014;124:1119-1126. Available at: https://www.ncbi.nlm.nih.gov/pubmed/24894769.

49. Fisher KE, Cohen C, Siddiqui MT, et al. Accurate detection of BRAF p.V600E mutations in challenging melanoma specimens requires stringent immunohistochemistry scoring criteria or sensitive molecular assays. Hum Pathol 2014;45:2281-2293. Available at: https://www.ncbi.nlm.nih.gov/pubmed/25228337.

50. Phan DAT, Phung GB, Duong TT, et al. The Value of BRAF VE1 Immunoexpression in Pediatric Langerhans Cell Histiocytosis. Fetal Pediatr Pathol 2022;41:558-567. Available at: https://www.ncbi.nlm.nih.gov/pubmed/33295826.

51. Ballester LY, Cantu MD, Lim KPH, et al. The use of BRAF V600E mutation-specific immunohistochemistry in pediatric Langerhans cell histiocytosis. Hematol Oncol 2018;36:307-315. Available at: https://www.ncbi.nlm.nih.gov/pubmed/28219109.

52. Chakraborty R, Hampton OA, Shen X, et al. Mutually exclusive recurrent somatic mutations in MAP2K1 and BRAF support a central role for ERK activation in LCH pathogenesis. Blood 2014;124:3007-3015. Available at: https://www.ncbi.nlm.nih.gov/pubmed/25202140.

53. Durham BH, Lopez Rodrigo E, Picarsic J, et al. Activating mutations in CSF1R and additional receptor tyrosine kinases in histiocytic neoplasms. Nat Med 2019;25:1839-1842. Available at: https://www.ncbi.nlm.nih.gov/pubmed/31768065.

54. Allen CE, Ladisch S, McClain KL. How I treat Langerhans cell histiocytosis. Blood 2015;126:26-35. Available at: https://www.ncbi.nlm.nih.gov/pubmed/25827831.

55. Laird J, Ma J, Chau K, et al. Outcome After Radiation Therapy for Langerhans Cell Histiocytosis Is Dependent on Site of Involvement. Int J Radiat Oncol Biol Phys 2018;100:670-678. Available at: https://www.ncbi.nlm.nih.gov/pubmed/29413280.

56. Heyd R, Strassmann G, Donnerstag F, et al. [Radiotherapy in Langerhans-cell histiocytosis. 2 case reports and review of the literature]. Rontgenpraxis 2000;53:51-61. Available at: https://www.ncbi.nlm.nih.gov/pubmed/10994366.

57. Sakai H, Ibe M, Takahashi H, et al. Satisfactory remission achieved by PUVA therapy in Langerhans cell hisiocytosis in an elderly patient. J Dermatol 1996;23:42-46. Available at: https://www.ncbi.nlm.nih.gov/pubmed/8720257.

58. Imafuku S, Shibata S, Tashiro A, Furue M. Cutaneous Langerhans cell histiocytosis in an elderly man successfully treated with narrowband ultraviolet B. Br J Dermatol 2007;157:1277-1279. Available at: https://www.ncbi.nlm.nih.gov/pubmed/17916205.

59. Hoeger PH, Nanduri VR, Harper JI, et al. Long term follow up of topical mustine treatment for cutaneous langerhans cell histiocytosis. Arch Dis Child 2000;82:483-487. Available at: https://www.ncbi.nlm.nih.gov/pubmed/10833183.

60. Kaneshima A, Yamaguchi S, Miyagi T, et al. Extracellular signal-regulated kinase activation of self-healing Langerhans cell histiocytosis: A case report. J Dermatol 2019;46:812-815. Available at: https://www.ncbi.nlm.nih.gov/pubmed/31271447.

61. Simko SJ, Garmezy B, Abhyankar H, et al. Differentiating skin-limited and multisystem Langerhans cell histiocytosis. J Pediatr 2014;165:990-996. Available at: https://www.ncbi.nlm.nih.gov/pubmed/25441388.

62. Chellapandian D, Makras P, Kaltsas G, et al. Bisphosphonates in Langerhans Cell Histiocytosis: An International Retrospective Case Series. Mediterr J Hematol Infect Dis 2016;8:e2016033. Available at: https://www.ncbi.nlm.nih.gov/pubmed/27413525.

63. Montella L, Merola C, Merola G, et al. Zoledronic acid in treatment of bone lesions by Langerhans cell histiocytosis. J Bone Miner Metab 2009;27:110-113. Available at: https://www.ncbi.nlm.nih.gov/pubmed/19018458.

Discussion update in progress

Version 2.2025 © 2025 National Comprehensive Cancer Network© (NCCN©), All rights reserved. NCCN Guidelines® and this illustration may not be reproduced in any form without the express written permission of NCCN.

PLEASE NOTE that use of this NCCN Content is governed by the End-User License Agreement, and you MAY NOT distribute this Content or use it with any artificial intelligence model or tool.
Printed by Máximo López Chenlo on 5/4/2026 6:21:12 PM. Copyright © 2026 National Comprehensive Cancer Network, Inc. All Rights Reserved.

64. De Benedittis D, Mohamed S, Rizzo L, et al. Indomethacin is an effective treatment in adults and children with bone Langerhans cell histiocytosis (LCH). Br J Haematol 2020;191:e109-e113. Available at: https://www.ncbi.nlm.nih.gov/pubmed/32862434.

65. Schonfeld N, Frank W, Wenig S, et al. Clinical and radiologic features, lung function and therapeutic results in pulmonary histiocytosis X. Respiration 1993;60:38-44. Available at: https://www.ncbi.nlm.nih.gov/pubmed/8469818.

66. Hyman DM, Puzanov I, Subbiah V, et al. Vemurafenib in Multiple Nonmelanoma Cancers with BRAF V600 Mutations. N Engl J Med 2015;373:726-736. Available at: https://www.ncbi.nlm.nih.gov/pubmed/26287849.

67. Diamond EL, Subbiah V, Lockhart AC, et al. Vemurafenib for BRAF V600-Mutant Erdheim-Chester Disease and Langerhans Cell Histiocytosis: Analysis of Data From the Histology-Independent, Phase 2, Open-label VE-BASKET Study. JAMA Oncol 2018;4:384-388. Available at: https://www.ncbi.nlm.nih.gov/pubmed/29188284.

68. Chang L, Lang M, Lin H, et al. Phase 2 study using low dose cytarabine for adult patients with newly diagnosed Langerhans cell histiocytosis. Leukemia 2024;38:803-809. Available at: https://www.ncbi.nlm.nih.gov/pubmed/38388646.

69. Hazim AZ, Ruan GJ, Ravindran A, et al. Efficacy of BRAF-Inhibitor Therapy in BRAF(V600E) -Mutated Adult Langerhans Cell Histiocytosis. Oncologist 2020;25:1001-1004. Available at: https://www.ncbi.nlm.nih.gov/pubmed/32985015.

70. Lorillon G, Jouenne F, Baroudjian B, et al. Response to Trametinib of a Pulmonary Langerhans Cell Histiocytosis Harboring a MAP2K1 Deletion. Am J Respir Crit Care Med 2018;198:675-678. Available at: https://www.ncbi.nlm.nih.gov/pubmed/29694792.

71. Messinger YH, Bostrom BC, Olson DR, et al. Langerhans cell histiocytosis with BRAF p.N486_P490del or MAP2K1 p.K57_G61del treated by the MEK inhibitor trametinib. Pediatr Blood Cancer 2020;67:e28712. Available at: https://www.ncbi.nlm.nih.gov/pubmed/32991018.

72. Papapanagiotou M, Griewank KG, Hillen U, et al. Trametinib-Induced Remission of an MEK1-Mutated Langerhans Cell Histiocytosis. JCO Precis Oncol 2017;1:1-5. Available at: https://www.ncbi.nlm.nih.gov/pubmed/35172489.

73. Awada G, Seremet T, Fostier K, et al. Long-term disease control of Langerhans cell histiocytosis using combined BRAF and MEK inhibition. Blood Adv 2018;2:2156-2158. Available at: https://www.ncbi.nlm.nih.gov/pubmed/30154124.

74. Cao XX, Li J, Zhao AL, et al. Methotrexate and cytarabine for adult patients with newly diagnosed Langerhans cell histiocytosis: A single arm, single center, prospective phase 2 study. Am J Hematol 2020;95:E235-E238. Available at: https://www.ncbi.nlm.nih.gov/pubmed/32395858.

75. Lin H, Chang L, Lang M, et al. Long-term follow-up of methotrexate and cytarabine in adult patients with Langerhans cell histiocytosis. Br J Haematol 2024. Available at: https://www.ncbi.nlm.nih.gov/pubmed/39428688.

76. Miao HL, Zhao AL, Duan MH, et al. Clinical presentation and prognostic analysis of adult patients with Langerhans cell histiocytosis with pulmonary involvement. BMC Cancer 2020;20:911. Available at: https://www.ncbi.nlm.nih.gov/pubmed/32967635.

77. Cantu MA, Lupo PJ, Bilgi M, et al. Optimal therapy for adults with Langerhans cell histiocytosis bone lesions. PLoS One 2012;7:e43257. Available at: https://www.ncbi.nlm.nih.gov/pubmed/22916233.

78. Simko SJ, Tran HD, Jones J, et al. Clofarabine salvage therapy in refractory multifocal histiocytic disorders, including Langerhans cell histiocytosis, juvenile xanthogranuloma and Rosai-Dorfman disease. Pediatr Blood Cancer 2014;61:479-487. Available at: https://www.ncbi.nlm.nih.gov/pubmed/24106153.

Discussion update in progress

Version 2.2025 © 2025 National Comprehensive Cancer Network© (NCCN©), All rights reserved. NCCN Guidelines® and this illustration may not be reproduced in any form without the express written permission of NCCN.

PLEASE NOTE that use of this NCCN Content is governed by the End-User License Agreement, and you MAY NOT distribute this Content or use it with any artificial intelligence model or tool.
Printed by Máximo López Chenlo on 5/4/2026 6:21:12 PM. Copyright © 2026 National Comprehensive Cancer Network, Inc. All Rights Reserved.

79. Ho P, Smith C. High-dose methotrexate for the treatment of relapsed central nervous system erdheim-chester disease. Case Rep Hematol 2014;2014:269359. Available at: https://www.ncbi.nlm.nih.gov/pubmed/25031876.

80. Womer RB, Anunciato KR, Chehrenama M. Oral methotrexate and alternate-day prednisone for low-risk Langerhans cell histiocytosis. Med Pediatr Oncol 1995;25:70-73. Available at: https://www.ncbi.nlm.nih.gov/pubmed/7603403.

81. Steen AE, Steen KH, Bauer R, Bieber T. Successful treatment of cutaneous Langerhans cell histiocytosis with low-dose methotrexate. Br J Dermatol 2001;145:137-140. Available at: https://www.ncbi.nlm.nih.gov/pubmed/11453923.

82. Zinn DJ, Grimes AB, Lin H, et al. Hydroxyurea: a new old therapy for Langerhans cell histiocytosis. Blood 2016;128:2462-2465. Available at: https://www.ncbi.nlm.nih.gov/pubmed/27688802.

83. Taylor J, Pavlick D, Yoshimi A, et al. Oncogenic TRK fusions are amenable to inhibition in hematologic malignancies. J Clin Invest 2018;128:3819-3825. Available at: https://www.ncbi.nlm.nih.gov/pubmed/29920189.

84. Drilon A, Laetsch TW, Kummar S, et al. Efficacy of Larotrectinib in TRK Fusion-Positive Cancers in Adults and Children. N Engl J Med 2018;378:731-739. Available at: https://www.ncbi.nlm.nih.gov/pubmed/29466156.

85. Doebele RC, Drilon A, Paz-Ares L, et al. Entrectinib in patients with advanced or metastatic NTRK fusion-positive solid tumours: integrated analysis of three phase 1-2 trials. Lancet Oncol 2020;21:271-282. Available at: https://www.ncbi.nlm.nih.gov/pubmed/31838007.

86. Solomon BJ, Drilon A, Lin JJ, et al. 1372P Repotrectinib in patients (pts) with NTRK fusion-positive (NTRK+) advanced solid tumors, including NSCLC: Update from the phase I/II TRIDENT-1 trial. Annals of Oncology 2023;34:S787-S788. Available at: https://doi.org/10.1016/j.annonc.2023.09.2405.

87. van Bommel EFH, van der Zijden MA, Smak Gregoor PJH, et al. Sirolimus monotherapy for Erdheim-Chester disease. Acta Oncol 2019;58:901-905. Available at: https://www.ncbi.nlm.nih.gov/pubmed/30919713.

88. Ingram W, Desai SR, Gibbs JS, Mufti G. Reduced-intensity conditioned allogeneic haematopoietic transplantation in an adult with Langerhans' cell histiocytosis and thrombocytopenia with absent radii. Bone Marrow Transplant 2006;37:713-715. Available at: https://www.ncbi.nlm.nih.gov/pubmed/16489360.

89. McClain KL, Kozinetz CA. A phase II trial using thalidomide for Langerhans cell histiocytosis. Pediatr Blood Cancer 2007;48:44-49. Available at: https://www.ncbi.nlm.nih.gov/pubmed/16333818.

90. Szturz P, Adam Z, Rehak Z, et al. Lenalidomide proved effective in multisystem Langerhans cell histiocytosis. Acta Oncol 2012;51:412-415. Available at: https://www.ncbi.nlm.nih.gov/pubmed/22103591.

91. Diamond EL, Dagna L, Hyman DM, et al. Consensus guidelines for the diagnosis and clinical management of Erdheim-Chester disease. Blood 2014;124:483-492. Available at: https://www.ncbi.nlm.nih.gov/pubmed/24850756.

92. Haroche J, Cluzel P, Toledano D, et al. Images in cardiovascular medicine. Cardiac involvement in Erdheim-Chester disease: magnetic resonance and computed tomographic scan imaging in a monocentric series of 37 patients. Circulation 2009;119:e597-598. Available at: https://www.ncbi.nlm.nih.gov/pubmed/19564564.

93. Brun AL, Touitou-Gottenberg D, Haroche J, et al. Erdheim-Chester disease: CT findings of thoracic involvement. Eur Radiol 2010;20:2579-2587. Available at: https://www.ncbi.nlm.nih.gov/pubmed/20563815.

94. Gianfreda D, Palumbo AA, Rossi E, et al. Cardiac involvement in Erdheim-Chester disease: an MRI study. Blood 2016;128:2468-2471. Available at: https://www.ncbi.nlm.nih.gov/pubmed/27663675.

Discussion update in progress

Version 2.2025 © 2025 National Comprehensive Cancer Network© (NCCN©), All rights reserved. NCCN Guidelines® and this illustration may not be reproduced in any form without the express written permission of NCCN.

PLEASE NOTE that use of this NCCN Content is governed by the End-User License Agreement, and you MAY NOT distribute this Content or use it with any artificial intelligence model or tool.
Printed by Máximo López Chenlo on 5/4/2026 6:21:12 PM. Copyright © 2026 National Comprehensive Cancer Network, Inc. All Rights Reserved.

95. Haroche J, Amoura Z, Dion E, et al. Cardiovascular involvement, an overlooked feature of Erdheim-Chester disease: report of 6 new cases and a literature review. Medicine (Baltimore) 2004;83:371-392. Available at: https://www.ncbi.nlm.nih.gov/pubmed/15525849.

96. Arnaud L, Pierre I, Beigelman-Aubry C, et al. Pulmonary involvement in Erdheim-Chester disease: a single-center study of thirty-four patients and a review of the literature. Arthritis Rheum 2010;62:3504-3512. Available at: https://www.ncbi.nlm.nih.gov/pubmed/20662053.

97. Estrada-Veras JI, O'Brien KJ, Boyd LC, et al. The clinical spectrum of Erdheim-Chester disease: an observational cohort study. Blood Adv 2017;1:357-366. Available at: https://www.ncbi.nlm.nih.gov/pubmed/28553668.

98. Serratrice J, Granel B, De Roux C, et al. "Coated aorta": a new sign of Erdheim-Chester disease. J Rheumatol 2000;27:1550-1553. Available at: https://www.ncbi.nlm.nih.gov/pubmed/10852289.

99. Cavalli G, Guglielmi B, Berti A, et al. The multifaceted clinical presentations and manifestations of Erdheim-Chester disease: comprehensive review of the literature and of 10 new cases. Ann Rheum Dis 2013;72:1691-1695. Available at: https://www.ncbi.nlm.nih.gov/pubmed/23396641.

100. Villatoro-Villar M, Bold MS, Warrington KJ, et al. Arterial involvement in Erdheim-Chester disease: A retrospective cohort study. Medicine (Baltimore) 2018;97:e13452. Available at: https://www.ncbi.nlm.nih.gov/pubmed/30544428.

101. Haroche J, Arnaud L, Amoura Z. Erdheim-Chester disease. Curr Opin Rheumatol 2012;24:53-59. Available at: https://www.ncbi.nlm.nih.gov/pubmed/22089098.

102. Dion E, Graef C, Haroche J, et al. Imaging of thoracoabdominal involvement in Erdheim-Chester disease. AJR Am J Roentgenol 2004;183:1253-1260. Available at: https://www.ncbi.nlm.nih.gov/pubmed/15505288.

103. Mazor RD, Manevich-Mazor M, Shoenfeld Y. Erdheim-Chester Disease: a comprehensive review of the literature. Orphanet J Rare Dis 2013;8:137. Available at: https://www.ncbi.nlm.nih.gov/pubmed/24011030.

104. Parks NE, Goyal G, Go RS, et al. Neuroradiologic manifestations of Erdheim-Chester disease. Neurol Clin Pract 2018;8:15-20. Available at: https://www.ncbi.nlm.nih.gov/pubmed/29517068.

105. Arnaud L, Hervier B, Neel A, et al. CNS involvement and treatment with interferon-alpha are independent prognostic factors in Erdheim-Chester disease: a multicenter survival analysis of 53 patients. Blood 2011;117:2778-2782. Available at: https://www.ncbi.nlm.nih.gov/pubmed/21239701.

106. Courtillot C, Laugier Robiolle S, Cohen Aubart F, et al. Endocrine Manifestations in a Monocentric Cohort of 64 Patients With Erdheim-Chester Disease. J Clin Endocrinol Metab 2016;101:305-313. Available at: https://www.ncbi.nlm.nih.gov/pubmed/26565949.

107. Papo M, Diamond EL, Cohen-Aubart F, et al. High prevalence of myeloid neoplasms in adults with non-Langerhans cell histiocytosis. Blood 2017;130:1007-1013. Available at: https://www.ncbi.nlm.nih.gov/pubmed/28679734.

108. Goyal G, Ravindran A, Liu Y, et al. Bone marrow findings in Erdheim-Chester disease: increased prevalence of chronic myeloid neoplasms. Haematologica 2020;105:e84-e86. Available at: https://www.ncbi.nlm.nih.gov/pubmed/31624111.

109. Pegoraro F, Papo M, Cohen-Aubart F, et al. Long-term outcome and prognosis of mixed histiocytosis (Erdheim-Chester disease and Langerhans Cell Histiocytosis). EClinicalMedicine 2024;73:102658. Available at: https://www.ncbi.nlm.nih.gov/pubmed/38841707.

110. Janku F, Diamond EL, Goodman AM, et al. Molecular Profiling of Tumor Tissue and Plasma Cell-Free DNA from Patients with Non-Langerhans Cell Histiocytosis. Mol Cancer Ther 2019;18:1149-1157. Available at: https://www.ncbi.nlm.nih.gov/pubmed/31015311.

Discussion update in progress

Version 2.2025 © 2025 National Comprehensive Cancer Network© (NCCN©), All rights reserved. NCCN Guidelines® and this illustration may not be reproduced in any form without the express written permission of NCCN.

PLEASE NOTE that use of this NCCN Content is governed by the End-User License Agreement, and you MAY NOT distribute this Content or use it with any artificial intelligence model or tool.
Printed by Máximo López Chenlo on 5/4/2026 6:21:12 PM. Copyright © 2026 National Comprehensive Cancer Network, Inc. All Rights Reserved.

111. Ozkaya N, Rosenblum MK, Durham BH, et al. The histopathology of Erdheim-Chester disease: a comprehensive review of a molecularly characterized cohort. Mod Pathol 2018;31:581-597. Available at: https://www.ncbi.nlm.nih.gov/pubmed/29192649.

112. Razanamahery J, Diamond EL, Cohen-Aubart F, et al. Erdheim-Chester disease with concomitant Rosai-Dorfman like lesions: a distinct entity mainly driven by MAP2K1. Haematologica 2020;105:e5-e8. Available at: https://www.ncbi.nlm.nih.gov/pubmed/31123032.

113. Ruan GJ, Hazim A, Abeykoon JP, et al. Low-dose vemurafenib monotherapy in BRAF(V600E) -mutated Erdheim-Chester disease. Leuk Lymphoma 2020;61:2733-2737. Available at: https://www.ncbi.nlm.nih.gov/pubmed/32608295.

114. Cohen Aubart F, Emile JF, Carrat F, et al. Targeted therapies in 54 patients with Erdheim-Chester disease, including follow-up after interruption (the LOVE study). Blood 2017;130:1377-1380. Available at: https://www.ncbi.nlm.nih.gov/pubmed/28667012.

115. Bhatia A, Ulaner G, Rampal R, et al. Single-agent dabrafenib for BRAF(V600E)-mutated histiocytosis. Haematologica 2018;103:e177-e180. Available at: https://www.ncbi.nlm.nih.gov/pubmed/29472347.

116. Janku F, Patel H, Raghavan VK, et al. MEK inhibition with trametinib in patients with non-Langerhans histiocytosis irrespective of BRAF mutation status. 2019 International ECD Medical Symposium 2019. Available at: https://doi.org/10.1182/blood-2019-126342.

117. Haroche J, Amoura Z, Trad SG, et al. Variability in the efficacy of interferon-alpha in Erdheim-Chester disease by patient and site of involvement: results in eight patients. Arthritis Rheum 2006;54:3330-3336. Available at: https://www.ncbi.nlm.nih.gov/pubmed/17009306.

118. Hervier B, Arnaud L, Charlotte F, et al. Treatment of Erdheim-Chester disease with long-term high-dose interferon-alpha. Semin Arthritis Rheum 2012;41:907-913. Available at: https://www.ncbi.nlm.nih.gov/pubmed/22300602.

119. Esmaeli B, Ahmadi A, Tang R, et al. Interferon therapy for orbital infiltration secondary to Erdheim-Chester disease. Am J Ophthalmol 2001;132:945-947. Available at: https://www.ncbi.nlm.nih.gov/pubmed/11730673.

120. Suzuki HI, Hosoya N, Miyagawa K, et al. Erdheim-Chester disease: multisystem involvement and management with interferon-alpha. Leuk Res 2010;34:e21-24. Available at: https://www.ncbi.nlm.nih.gov/pubmed/19679354.

121. Osman S, Chia JC, Street L, et al. Transitioning to Pegylated Interferon for the Treatment of Cutaneous T-Cell Lymphoma: Meeting the Challenge of Therapy Discontinuation and a Proposed Algorithm. Dermatologic Therapy 2023;2023:7171937. Available at: https://onlinelibrary.wiley.com/doi/abs/10.1155/2023/7171937.

122. Patsatsi A, Papadavid E, Kyriakou A, et al. The use of pegylated interferon a-2a in a cohort of Greek patients with mycosis fungoides. J Eur Acad Dermatol Venereol 2022;36:e291-e293. Available at: https://www.ncbi.nlm.nih.gov/pubmed/34753217.

123. Schiller M, Tsianakas A, Sterry W, et al. Dose-escalation study evaluating pegylated interferon alpha-2a in patients with cutaneous T-cell lymphoma. J Eur Acad Dermatol Venereol 2017;31:1841-1847. Available at: https://www.ncbi.nlm.nih.gov/pubmed/28557110.

124. Goyal G, Shah MV, Call TG, et al. Clinical and Radiologic Responses to Cladribine for the Treatment of Erdheim-Chester Disease. JAMA Oncol 2017;3:1253-1256. Available at: https://www.ncbi.nlm.nih.gov/pubmed/28253394.

125. Gianfreda D, Nicastro M, Galetti M, et al. Sirolimus plus prednisone for Erdheim-Chester disease: an open-label trial. Blood 2015;126:1163-1171. Available at: https://www.ncbi.nlm.nih.gov/pubmed/26041743.

126. Goyal G, Shah MV, Call TG, et al. Clinical and radiological responses to oral methotrexate alone or in combination with other

Discussion update in progress

Version 2.2025 © 2025 National Comprehensive Cancer Network© (NCCN©), All rights reserved. NCCN Guidelines® and this illustration may not be reproduced in any form without the express written permission of NCCN.

PLEASE NOTE that use of this NCCN Content is governed by the End-User License Agreement, and you MAY NOT distribute this Content or use it with any artificial intelligence model or tool.
Printed by Máximo López Chenlo on 5/4/2026 6:21:12 PM. Copyright © 2026 National Comprehensive Cancer Network, Inc. All Rights Reserved.

agents in Erdheim-Chester disease. Blood Cancer J 2017;7:647. Available at: https://www.ncbi.nlm.nih.gov/pubmed/29242623.

127. Cohen-Aubart F, Maksud P, Saadoun D, et al. Variability in the efficacy of the IL1 receptor antagonist anakinra for treating Erdheim-Chester disease. Blood 2016;127:1509-1512. Available at: https://www.ncbi.nlm.nih.gov/pubmed/26847247.

128. Goyal G, Shah MV, Call TG, et al. Efficacy of biological agents in the treatment of Erdheim-Chester disease. Br J Haematol 2018;183:520-524. Available at: https://www.ncbi.nlm.nih.gov/pubmed/29082516.

129. Kemps PG, Picarsic J, Durham BH, et al. ALK-positive histiocytosis: a new clinicopathologic spectrum highlighting neurologic involvement and responses to ALK inhibition. Blood 2022;139:256-280. Available at: https://www.ncbi.nlm.nih.gov/pubmed/34727172.

130. Abeykoon JP, Lasho TL, Dasari S, et al. Sustained, complete response to pexidartinib in a patient with CSF1R-mutated Erdheim-Chester disease. Am J Hematol 2022;97:293-302. Available at: https://www.ncbi.nlm.nih.gov/pubmed/34978715.

131. Li W. The 5(th) Edition of the World Health Organization Classification of Hematolymphoid Tumors. In: Li W, ed. Leukemia. Brisbane (AU): Exon Publications; 2022.

132. Abla O, Jacobsen E, Picarsic J, et al. Consensus recommendations for the diagnosis and clinical management of Rosai-Dorfman-Destombes disease. Blood 2018;131:2877-2890. Available at: https://www.ncbi.nlm.nih.gov/pubmed/29720485.

133. Goyal G, Ravindran A, Young JR, et al. Clinicopathological features, treatment approaches, and outcomes in Rosai-Dorfman disease. Haematologica 2020;105:348-357. Available at: https://www.ncbi.nlm.nih.gov/pubmed/31004029.

134. Juskevicius R, Finley JL. Rosai-Dorfman disease of the parotid gland: cytologic and histopathologic findings with immunohistochemical correlation. Arch Pathol Lab Med 2001;125:1348-1350. Available at: https://www.ncbi.nlm.nih.gov/pubmed/11570913.

135. Sandoval-Sus JD, Sandoval-Leon AC, Chapman JR, et al. Rosai-Dorfman disease of the central nervous system: report of 6 cases and review of the literature. Medicine (Baltimore) 2014;93:165-175. Available at: https://www.ncbi.nlm.nih.gov/pubmed/24797172.

136. Andriko JA, Morrison A, Colegial CH, et al. Rosai-Dorfman disease isolated to the central nervous system: a report of 11 cases. Mod Pathol 2001;14:172-178. Available at: https://www.ncbi.nlm.nih.gov/pubmed/11266522.

137. Molho-Pessach V, Ramot Y, Camille F, et al. H syndrome: the first 79 patients. J Am Acad Dermatol 2014;70:80-88. Available at: https://www.ncbi.nlm.nih.gov/pubmed/24172204.

138. Mahajan S, Nakajima R, Yabe M, et al. Rosai-Dorfman Disease-Utility of 18F-FDG PET/CT for Initial Evaluation and Follow-up. Clin Nucl Med 2020;45:e260-e266. Available at: https://www.ncbi.nlm.nih.gov/pubmed/32349088.

139. Cartin-Ceba R, Golbin JM, Yi ES, et al. Intrathoracic manifestations of Rosai-Dorfman disease. Respir Med 2010;104:1344-1349. Available at: https://www.ncbi.nlm.nih.gov/pubmed/20418084.

140. Baraban E, Sadigh S, Rosenbaum J, et al. Cyclin D1 expression and novel mutational findings in Rosai-Dorfman disease. Br J Haematol 2019;186:837-844. Available at: https://www.ncbi.nlm.nih.gov/pubmed/31172509.

141. Deshpande V, Zen Y, Chan JK, et al. Consensus statement on the pathology of IgG4-related disease. Mod Pathol 2012;25:1181-1192. Available at: https://www.ncbi.nlm.nih.gov/pubmed/22596100.

142. Ravindran A, Goyal G, Go RS, et al. Rosai-Dorfman Disease Displays a Unique Monocyte-Macrophage Phenotype Characterized by Expression of OCT2. Am J Surg Pathol 2021;45:35-44. Available at: https://www.ncbi.nlm.nih.gov/pubmed/33177341.

Discussion update progress

Version 2.2025 © 2025 National Comprehensive Cancer Network© (NCCN©), All rights reserved. NCCN Guidelines® and this illustration may not be reproduced in any form without the express written permission of NCCN.

PLEASE NOTE that use of this NCCN Content is governed by the End-User License Agreement, and you MAY NOT distribute this Content or use it with any artificial intelligence model or tool.
Printed by Máximo López Chenlo on 5/4/2026 6:21:12 PM. Copyright © 2026 National Comprehensive Cancer Network, Inc. All Rights Reserved.

143. Garces S, Medeiros LJ, Patel KP, et al. Mutually exclusive recurrent KRAS and MAP2K1 mutations in Rosai-Dorfman disease. Mod Pathol 2017;30:1367-1377. Available at: https://www.ncbi.nlm.nih.gov/pubmed/28664935.

144. Maklad AM, Bayoumi Y, Tunio M, et al. Steroid-resistant extranodal rosai-dorfman disease of cheek mass and ptosis treated with radiation therapy. Case Rep Hematol 2013;2013:428297. Available at: https://www.ncbi.nlm.nih.gov/pubmed/23738161.

145. Toguri D, Louie AV, Rizkalla K, et al. Radiotherapy for steroid-resistant laryngeal Rosai-Dorfman disease. Curr Oncol 2011;18:e158-162. Available at: https://www.ncbi.nlm.nih.gov/pubmed/21655154.

146. Abeykoon JP, Rech KL, Young JR, et al. Outcomes After Treatment With Cobimetinib in Patients With Rosai-Dorfman Disease Based on KRAS and MEK Alteration Status. JAMA Oncol 2022;8:1816-1820. Available at: https://www.ncbi.nlm.nih.gov/pubmed/36201194.

147. Namoglu EC, Hughes ME, Plastaras JP, et al. Management and outcomes of sinus histiocytosis with massive lymphadenopathy (Rosai Dorfman Disease). Leuk Lymphoma 2020;61:905-911. Available at: https://www.ncbi.nlm.nih.gov/pubmed/31876204.

148. Nasseri E, Belisle A, Funaro D. Rosai-Dorfman disease treated with methotrexate and low-dose prednisone: case report and review of the literature. J Cutan Med Surg 2012;16:281-285. Available at: https://www.ncbi.nlm.nih.gov/pubmed/22784522.

149. Wang W, Sun J, Zhang W, Zhou D. Successful treatment of intracranial Rosai-Dorfman disease with cytarabine and dexamethasone: case report and review of literature. Ann Hematol 2020;99:1157-1159. Available at: https://www.ncbi.nlm.nih.gov/pubmed/32236734.

150. Nadal M, Kervarrec T, Machet MC, et al. Cutaneous Rosai-Dorfman Disease Located on the Breast: Rapid Effectiveness of Methotrexate After Failure of Topical Corticosteroids, Acitretin and Thalidomide. Acta Derm Venereol 2015;95:758-759. Available at: https://www.ncbi.nlm.nih.gov/pubmed/25632986.

151. Chen E, Pavlidakey P, Sami N. Rosai-Dorfman disease successfully treated with thalidomide. JAAD Case Rep 2016;2:369-372. Available at: https://www.ncbi.nlm.nih.gov/pubmed/27709124.

152. Inoue S, Onwuzurike N. Venorelbine and methotrexate for the treatment of Rosai-Dorfman disease. Pediatr Blood Cancer 2005;45:84-85; author reply 86. Available at: https://www.ncbi.nlm.nih.gov/pubmed/15838858.

153. Teachey DT, Greiner R, Seif A, et al. Treatment with sirolimus results in complete responses in patients with autoimmune lymphoproliferative syndrome. Br J Haematol 2009;145:101-106. Available at: https://www.ncbi.nlm.nih.gov/pubmed/19208097.

154. Cooper SL, Arceci RJ, Gamper CJ, et al. Successful Treatment of Recurrent Autoimmune Cytopenias in the Context of Sinus Histiocytosis With Massive Lymphadenopathy Using Sirolimus. Pediatr Blood Cancer 2016;63:358-360. Available at: https://www.ncbi.nlm.nih.gov/pubmed/26452062.

155. Aaroe A, Kurzrock R, Goyal G, et al. Successful treatment of non-Langerhans cell histiocytosis with the MEK inhibitor trametinib: a multicenter analysis. Blood Adv 2023;7:3984-3992. Available at: https://www.ncbi.nlm.nih.gov/pubmed/36857436.

156. Cohen-Barak E, Rozenman D, Schafer J, et al. An unusual co-occurrence of Langerhans cell histiocytosis and Rosai-Dorfman disease: report of a case and review of the literature. Int J Dermatol 2014;53:558-563. Available at: https://www.ncbi.nlm.nih.gov/pubmed/23968608.

157. Al-Ghawas MS, Ng T, Chen LYC. Confirmed Efficacy of Lenalidomide and Dexamethasone in Unresectable Cutaneous Facial Rosai-Dorfman-Destombes Disease. Mayo Clin Proc Innov Qual Outcomes 2019;3:94-96. Available at: https://www.ncbi.nlm.nih.gov/pubmed/30899913.

Discussion update in progress

Version 2.2025 © 2025 National Comprehensive Cancer Network© (NCCN©), All rights reserved. NCCN Guidelines® and this illustration may not be reproduced in any form without the express written permission of NCCN.

PLEASE NOTE that use of this NCCN Content is governed by the End-User License Agreement, and you MAY NOT distribute this Content or use it with any artificial intelligence model or tool.
Printed by Máximo López Chenlo on 5/4/2026 6:21:12 PM. Copyright © 2026 National Comprehensive Cancer Network, Inc. All Rights Reserved.

158. Rubinstein M, Assal A, Scherba M, et al. Lenalidomide in the treatment of Rosai Dorfman disease--a first in use report. Am J Hematol 2016;91:E1. Available at: https://www.ncbi.nlm.nih.gov/pubmed/26502013.

159. Golwala ZM, Taur P, Pandrowala A, et al. Sirolimus-A targeted therapy for Rosai-Dorfman disease. Pediatr Blood Cancer 2019;66:e27994. Available at: https://www.ncbi.nlm.nih.gov/pubmed/31524314.

160. Rituximab in the treatment of Rosai-Dorfman syndrome with IgG4 disease. Journal of the American Academy of Dermatology 2019;81:AB269. Available at: https://doi.org/10.1016/j.jaad.2019.06.1173.

161. Diamond EL, Reiner AS, Buthorn JJ, et al. A scale for patient-reported symptom assessment for patients with Erdheim-Chester disease. Blood Adv 2019;3:934-938. Available at: https://www.ncbi.nlm.nih.gov/pubmed/30917949.

162. O'Brien K, Dave R, Shekhar S, et al. Survivorship Issues in Adult Patients With Histiocytic Neoplasms. J Natl Compr Canc Netw 2021;19:1312-1318. Available at: https://www.ncbi.nlm.nih.gov/pubmed/34781266.

Discussion update in progress

Version 2.2025 © 2025 National Comprehensive Cancer Network© (NCCN©), All rights reserved. NCCN Guidelines® and this illustration may not be reproduced in any form without the express written permission of NCCN.